

# Compare the accuracy of diagnosis based on the stroboscopy and pathological report

Nader Saki<sup>1</sup>, Karen Menhas<sup>2</sup>, Soheila Nikakhlagh<sup>1</sup>, Mojtaba Lotfinia<sup>3\*</sup>, Hassan Abshirini<sup>1</sup>

<sup>1</sup> Associate professor of otolaryngology, Head and neck surgery, Hearing Research Center, Ahvaz Jundishapur University of Medical Sciences, Ahvaz, Iran. <sup>2</sup> General Physician, Hearing Research Center, Ahvaz Jundishapur University of Medical Sciences, Ahvaz, Iran. <sup>3</sup> Resident of otolaryngology, Head and neck surgery, Hearing Research Center, Ahvaz Jundishapur University of Medical Sciences, Ahvaz, Iran.

**Correspondence:** Mojtaba Lotfinia, Emam hospital, Ahvaz Jundishapur University of Medical Sciences, Ahvaz, Iran. Tel :06132921838, Email: laftee.a@ajums.ac.ir, mojtabamed@gmail.com

## ABSTRACT

**Background and Objective:** A wide variety of benign and malignant lesions from the squamous and mesenchymal epithelium occur in the larynx. Among these vocal cord polyps, nodules, papilloma, and squamous cell carcinoma have significant outbreak. The aim of this study was to compare the accuracy of diagnosis based on the stroboscopy and confirmation by the pathological report. **Materials and Methods:** This is an analytic epidemiological study on 139 patients with complaint of hoarseness. The symptoms and physical examination were taken from patients. Stroboscopic technique was done for them. The biopsy taken in a case of mass form lesions. Pathological diagnosis was reported in patients' form. Stroboscopic study and pathologic report were compared. Collected data was analyzed using SPSS software (version 22). **Results:** Laryngeal mass were divided into four groups: malignancy, nodule, ployp and miscellaneous. In stroboscopic study, malignancy group (25 cases =18.0%), Nodule group( 83 cases=59.7%), Ployp group (27 cases=19.4%), and in miscellaneous group(4 cases =2.9%) were defined. And according to the pathological report in malignancy group(25 cases =18.0%), Nodule group( 84 cases=60.4%), Ployp group (14 cases=10.1%) and in miscellaneous group (16 cases =11.5%), were defined. **Conclusion:** The stroboscopy can be very useful technique in the initial study of laryngopharyngeal lesions. for diagnosis of laryngopharyngeal tumoral lesions, pathological report is the gold standard. But still biopsy is a prerequisite for the pathological report, in other words, surgical intervention.

**Keywords:** laryngopharyngeal lesions, Stroboscopy, Pathology

## Introduction

A wide range of non-cancerous diseases, benign and malignant originated from the squamous and mesenchymal epithelium occur in the laryngopharynx and among these types, polyps, vocal cord nodules, papilloma, and squamous cell carcinoma are more common. Hoarseness is the most common symptom. Vocal cord polyp is a hemispherical smooth prominence, (Usually with a diameter of less than 0.5cm), which often were placed on true vocal cords. This lesion is caused by chronic

irritation and voice abuse [1-3].

Laryngeal papilloma or laryngeal squamous papilloma is a benign neoplastic lesion, which is usually developed on the true vocal cords and constitutes the softness raspberry-like growth that is rarely greater than 1cm. During the recent years, biomarkers are used to predict disease progression or treatment response. [1-5].

Usually, papilloma is single growth in adult but multiple in children, so called "the laryngeal papillomatosis of teenagers". Laryngeal papillomatosis is caused by human papilloma virus type of 6 and 11, and usually was not malignant and disappear spontaneously at puberty. In children, these tumors can recur frequently, may require repetitive surgery and transformation to malignancy is rare. Incidence of laryngeal carcinoma is only 2% of all cancers. Usually occurs after age 40 and in males is 7 times more common than females (proportion 7 to 1). Environmental factors play significant role in its development; most of cases were smokers, alcoholics and asbestos may be

## Access this article online

Website: [www.japer.in](http://www.japer.in)

E-ISSN: 2249-3379

**How to cite this article:** Nader Saki, Karen Menhas, Soheila Nikakhlagh, Mojtaba Lotfinia, Hassan Abshirini. Compare the accuracy of diagnosis based on the stroboscopy and pathological report. J Adv Pharm Edu Res 2019;9(S2):131-134.

**Source of Support:** Nil, Conflict of Interest: None declared.

This is an open access journal, and articles are distributed under the terms of the Creative Commons Attribution-Non Commercial-ShareAlike 4.0 License, which allows others to remix, tweak, and build upon the work non-commercially, as long as appropriate credit is given and the new creations are licensed under the identical terms.

other risk factors. The tumor is usually seen on the vocal cord in 75% - 60% of all cases, but also can be seen in supraglottis (40%-25%) or Subglottis (<5%). SCC of the larynx, shows a strong association with tobacco smoking, alcohol consumption and x-ray exposure. The tumor site in the larynx has a significant role on prognosis. For example, about 90% of the glottis tumors are limited to the larynx at the time of diagnosis. On the contrary, supraglottis area includes many lymph nodes and in one third of these tumors the lymph nodes were involved. Subglottic tumors are clinically silent and usually the symptoms are very advanced at time of advent. With surgery, radiation, and complex treatment regimens, many patients can be cured, but one third of them die due to illness. During the recent years using biomarkers for predicting disease progression or predicting treatment response has been dramatically developed [2, 4, 5].

All patients who have laryngeal complaints, their larynx should be seen directly or indirectly. The main screening test of larynx is indirect laryngoscopy and has provided a good view of the larynx and hypopharynx and can evaluate the vocal cord mobility. Videostroboscopy is an excellent technique to evaluate the laryngopharynx. Videostroboscopy can be done by using rigid or flexible endoscope. Larynx electromyography (LEMG) is measurement technique of generated electrical impulses by the muscles of the larynx. Its clinical applications are still expanding. Imaging techniques also be used such as barium swallow, MRI, CT scan, angiography, nuclear scans, sonography. The aim of this study is the differential diagnosis of pharynx and larynx lesions by using stroboscopic technique and compared with results obtained concordance the pathology report in Ahvaz Imam Hospital.

## Materials and Methods

In this study, 139 patients, Those who were admitted with complaints of hoarseness were evaluated. At first, the history and physical examination were taken from patients. Patients who were candidate for stroboscopic study were selected and information obtained were recorded on a separate form for each patient. All patients whose laryngeal mass were seen in stroboscopic report candidate for biopsy. Only those who stroboscopic study were done and a biopsy was necessary in the process of their diagnosis plan, were selected for this study. Then, the patient underwent laryngeal surgery and biopsy. biopsy specimens assessed by pathologist and information obtained and pathological diagnosis were recorded in patients' form. Collected data analyzed using SPSS software (version 22).

## Results

Among 139 studied patients, 101 patients male (72.7%) and 38 patients were female (27.3%). (Chart 1). The age range was between 2 and 9 decades of life and patients age mean was about 56 years. Patients differential lesions of laryngeal tumors were divided into four groups: malignancy, nodule, polyp and

other lesions. In stroboscopic study in groups of malignancies 25 cases (18.0%), nodules 83(59.7%), polyps 27(19.4%) and in other lesions group (2.9%) were seen(Chart 2).

In the pathologic assessment in groups of malignancies 25(18.0%) [Include 23 men and 2 women], nodule 84 cases (60.4%) [Include 54 males and 30 females], polyps 14 patients (10.1%) [Include 12 males and 2 females], and other lesions group 16 Patients were seen (11.5%) [Include 82 men and 4 women] (Chart 3). In conducted survey, which were in the other lesions group included inflammation, cyst, keratosis, contact ulcer, pleomorphic adenoma, granulation tissue, lipoma. To evaluate the stroboscopic diagnostic value, the sensitivity and specificity was calculated based on results comparison of pathologic. Based on results obtained, each group from three groups of malignancy, nodule and polyp was separately studied and analyzed.

In malignancies group, there was the number of 18 cases of true positive and 7 cases of false positive. Also, the number of true negative and false negative was respectively 107 and 7 cases.

Based on this statistics, sensitivity and specificity rate was calculated as following.

$$\frac{18}{18+7} = \frac{18}{25} = 72.5\% = (\text{Sensitivity})$$

$$\frac{107}{107+7} = \frac{107}{114} = 93.8\% = (\text{Specificity})$$

Based on sensitivity and specificity rate was earned respectively 72.5% and 93.8%.

In nodule group, true positive cases was reported 74 cases and false positive 9 cases. Also, the number of true negative cases 49 and false negative cases 10 was earned.

According to these results, sensitivity and specificity rate was calculated as following.

$$(\text{sensitivity}) = \frac{74}{74+16} = \frac{74}{90} = 82.2\%$$

$$(\text{Specificity}) = \frac{46}{46+9} = \frac{46}{55} = 83.6\%$$

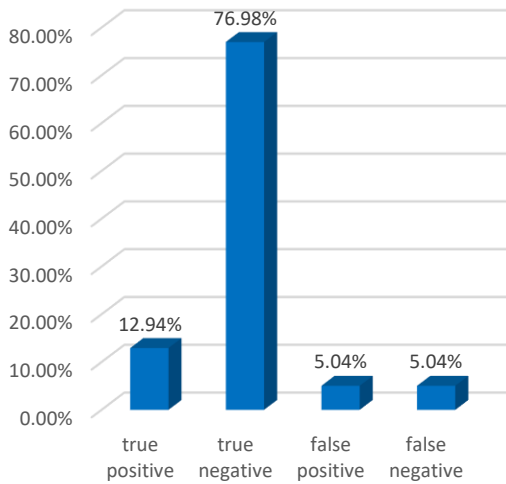
Based on sensitivity and specificity rate was earned respectively 82.2% and 83.6%.

In group of polyp diagnosis was earned true positive rate 12 cases and false positive 15 cases. As well as the number of true negative cases 110 and false negative cases 2 was reported. Based on these results, sensitivity and specificity rate was calculated as following.

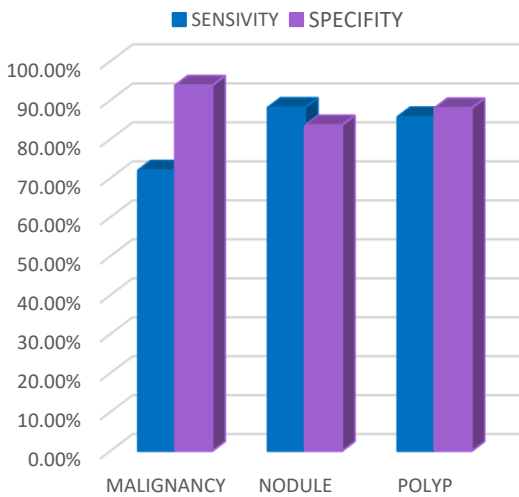
$$(\text{Sensitivity}) = \frac{12}{12+2} = \frac{12}{14} = 85.7\%$$

$$(\text{Specificity}) = \frac{110}{110+15} = \frac{110}{125} = 88.0\%$$

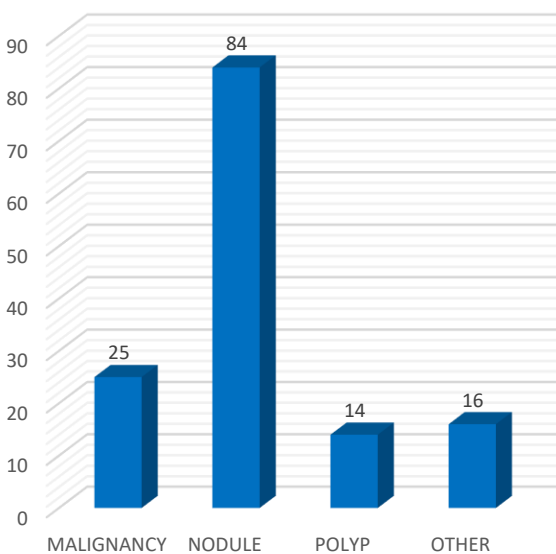
Based on sensitivity and specificity rate was earned respectively 85.7% and 88%.



**Chart 1.** Comparison chart of stroboscopic detection with pathology about the nodule



**Chart 2.** sensitivity rate and stroboscopic detection feature



**Chart 3.** Frequency chart of the differential diagnosis of laryngeal tumors based on pathology

## Discussion

The most common Complaint of laryngopharynx problem is hoarseness [3]. For detection of lesions in patients that complain of hoarseness history, physical exam and laryngoscopy examination (Direct and indirect) is important [6]. Many studies have determined that stroboscopic technique in considerable partly cases, facilitate the definit diagnosis of laryngeal lesions. The detection change in different studies is reported between 10 to 33% and diagnosis improvement by the stroboscopic technique is reported about 29% [7, 8]. In Satalof et al. study which was conducted as prospective, stroboscopic in 29% cases was added the cases to the recognition and in 18% of recognition cases was incorrect before stroboscopic; in study which conducted by Talof and Siegel, in one third of patients who there was stereoscopy indication in them, stereoscopy changes diagnosis or treatment or both [7, 9]. Casiano et al. stated in their study that in 14% of cases, video stroboscopic changed detection and subsequent treatment [2]. Also, in Woo and et al. study which was as prospective, was specified that in 10% of cases compared with indirect laryngoscopy or laryngoscopy fiberoptic, stroboscopy implementation was led to a change in diagnosis which these changes had the highest incidence of benign lesions of the larynx [10]. Also in comparison with pathology, the superiority of stroboscopy is being fast and the ability of its fulfillment before surgery intervention. During the search among articles and previously carried out studies, the case from studies was not found that be paid to survey of the diagnostic value of stroboscopic. In our country, the only study that is done on the stroboscopy, only is discussed to prevalence detection of differentials of hoarseness factors as well [6]. The introduction of video stroboscope into Otolaryngology practice has revolutionized the assessment of vocal cord pathology [9]. In our study it was found that laryngeal masses have more prevalence in men than women (72.7% vs. 27.3%) that this superiority was more related to malignant lesions and polyps. In laryngeal mass like lesions in different decades of age, the highest incidence of the masses was in the middle decades of a certain life so ,fourth, fifth and sixth decade of life. Malignant lesions prevalence increased with aging so that prevalence of polyp and nodule diagnosis reach to zero in the eighth and ninth decades and in decades of all patients age have malignancy diagnosis in pathology. The highest incidence of nodules is in the fourth and fifth decades of life (respectively, 1. 86% 7. 66). The highest prevalence of polyp in the decades of the fourth, fifth and sixth of life was (respectively, 3. 8%, 1%. 9 and 7. 10%). These results with lesions prevalence are almost close in previous studies and are confirming of previous results. In our study we found that stroboscopy has a good diagnostic value for diagnosis of mass like lesions of the larynx. About the diagnosis of malignancies in our study, sensitivity of stroboscopic detection was obtained to 79% rate. The rate of stroboscopic detection feature about malignancies was also 93% that is a very good rate. These numbers show that in segregation benign from

malignant lesions, the evaluation of stroboscopic has very high value.

The false positive rate was 7% and false negative rate also was 7%. The rate of false negative was especially about small dimensions and well differentiated tumors. According to results obtained, it seems that stroboscopic value in the diagnosis of malignant lesions is good. Also, the presence of keratosis in lesions liken the tumor appearance to malignant lesions and these cases raise the false positive results in studies. In part of nodules study, the sensitivity rate of detection was 88.1% and its feature was obtained 83.6%.

Therefore, with stroboscopic study, a large majority of nodules are detected and this detection has also high feature<sup>[11]</sup>. False positive rate was about 4% and false negative rate was reported 10%. In conducted survey found that the most of these interactions were with polyp lesions and with low grade malignancies. In the polyps lesions study by stroboscopy, the rate of detection sensitivity was obtained 85.7% and also its feature rate was reported 88%. In this part, sensitivity and specificity rate of diagnosis was obtained partly high and such concluded that stroboscopic detection sensitivity in the diagnosis of polyp lesions is important. Also, false positive rate 15% and false negative rate was earned 2%.

Nodule have been detected in the majority of cases with false positives pathological report and were also observed the nodules that have more bumps from level of larynx wall, more likely to be confused with polyp. According to very low false negative in polyp detection by stroboscopy, it seems that in other diagnostic with stroboscopy, false positive cases in the detection of nodule and malignancy are confused together.

## Acknowledgements

This article is the result of an M.D. thesis. The ethic committee code was 122. The project was completely funded by the Research Deputy. Authors would like to thank Research Deputy of Faculty of Medicine and Centers for Diabetes and Hearing Research

## Conflict of Interest

No potential conflict of interest relevant to this article was reported.

## References

1. Nader Saki, Nikakhlagh Soheila , Rahim Fakher, Fatehizade Payam. Endolaryngeal lipoma: case report and literature review. *Ear Nose & Throat Journal*.2012;vol 91(2);18-21. PMID: 22359140.
2. Casiano RR, Zaveri V, Lundy DS. Efficacy of videostroboscopy in the diagnosis of voice disorders. *Otolaryngology--Head and Neck Surgery*. 1992;107(1):95-100. DOI: 10.1177/019459989210700115.
3. M. Abtahi MH, M. Regha'a. The results survey of direct laryngoscopy of patients with chronic hoarseness over a period of 8 years. Isfahan: Ayatollah Kashani Hospital.1991-9.
4. Spiegel JR, Sataloff RT, Hawkshaw MJ. Stroboscopy: results and clinical value. *Annals of Otology, Rhinology & Laryngology*. 1991;100(9):725-7.
5. Woo P, Colton R, Casper J, Brewer D. Diagnostic value of stroboscopic examination in hoarse patients. *Journal of voice*. 1991;5(3):231-8. DOI: [https://doi.org/10.1016/S0892-1997\(05\)80191-2](https://doi.org/10.1016/S0892-1997(05)80191-2).
6. Nikakhlagh S,Saki N , Emad Mostofi N, Peyvasteh M. Rhabdomyosarcoma of the larynx. *Pak J Med Sci* 2007 Vol. 23 No. 2.
7. Rajput SD et al.stroboscopy:An evolving tool for voice analysis in vocal cord pathologies *International Journal of Otorhinolaryngology and Head and Neck surgery* .2017 oct;(3)4:3:927-931. DOI: <http://dx.doi.org/10.18203/issn.2454-5929.ijohns20173265>.
8. Saki N, Nik Akhlagh S, Mostofi NE, Ahmadi K, "Chondrosarcoma of the hyoid bone: imaging, surgical, and histopathologic correlation," *Laryngoscope*.2008; vol. 118, no. 7, pp. 1211–1213. doi: 10.1097/MLG.0b013e318170f8bd.
9. Sataloff, R.T., Spiegel, J.R. and Hawkshaw, M.J. Stroboscopy: Results and Clinical Value *Annals of Otology, Rhinology & Laryngology*.1991;100, 725-727. <https://doi.org/10.1177/000348949110000907>.
10. Satalof RT, Castell D, Sataloff D, Spiegel JR, Hawkshaw M. Reflux and other gastroenterologic conditions that may affect the voice. In Sataloff RT. *Professional Voice. The Science and Art to Clinical Care* 1997; 2 ed. San Diego, Singular.
11. Mehta, D.D. and Hillman, R.E. Current Role of Stroboscopy in Laryngeal Imaging. *Current Opinion in Otolaryngology & Head and Neck Surgery*.2012; 20, 429-436. <http://dx.doi.org/10.1097/MOO.0b013e3283585f04>