

An unusual long standing bronchial foreign body (Case report of thumbtack)

Shohreh Norouzi¹, Sara Saki^{2*}, Iman Mohammadi³

¹ Otolaryngologist, Hearing research center, Ahvaz jundishapur university of medical sciences, Ahvaz, Iran. ² Medical Intern, International Campus, Tehran University of Medical Sciences, Tehran, Iran. ³ Resident of otolaryngology, Hearing research center, Ahvaz jundishapur university of medical sciences, Ahvaz, Iran

Correspondence: Sara Saki. Medical Intern, International Campus, Tehran University of Medical Sciences, Tehran, Iran. ssaki_ir@yahoo.com

ABSTRACT

The foreign body aspiration and the related complications is one of the issues greatly observed in the emergency departments. The patient was a 61-year-old woman who did not have any history of disease. She suffered from repetitive coughs and Pneumonia, had visited the physician several times, and was treated by outpatient medical treatment. However, her problem still existed. All of the tests of the patient were normal and chest radiography was done for diagnosing pulmonary problems. Accidentally, a foreign body was observed in the right bronchus of the patient. The patient was examined and she was candidate for rigid bronchoscopy. After doing the operation, a rusty thumbtack was observed in the left bronchus of the patient and it was removed.

Keywords: thumbtack, aspiration, rigid bronchoscopy, foreign body, long standing

Introduction

The foreign body aspiration in trachea and bronchus can be seen in all age groups; they are often seen in childhood. In such cases, it is needed to be quickly diagnosed and the foreign body should be securely removed [1]. The aspirations of the foreign body are one of the important reasons for death across the world; they mainly take place in the lower-than-15-year-old children and the elderly [2]. The foreign body aspiration causes over 3000 deaths in the world per year. Approximately, 75 to 85 percent of all of the aspirations of the foreign body takes place in lower-than-15-year-old children. However, most of them are lower than 3 years old [3]. In this study, a rare case of foreign body aspiration was reported in the adults. It has been placed in bronchus for a long time without any sign.

Introduction of the case

The patient was a 61-year-old woman without any previous

physical or mental disease. She suffered from repetitive coughs and Pneumonia, had visited the physician several times, and was treated by outpatient medical treatment. However, her problem still existed. She referred to Imam Khomeini Hospital in Ahvaz and was hospitalized in the pulmonary diseases ward by the order of the physicians of the patient in the internal service and in a sub-specialist way. All of the tests of the patient were normal and chest radiography was done for diagnosing pulmonary problems. Accidentally, a foreign body was observed in the left bronchus of the patient. The patient was asked to refer to an otorhinolaryngologist. The patient was examined and she was candidate for rigid bronchoscopy. After doing the operation, a rusty thumbtack was observed in the left bronchus (Fig. 1) of the patient and it was removed.

Discussion

The foreign body aspiration is an emergency medical situation that needs timely diagnosis and action. Its rate of death had been high before the invention of bronchoscope. Gösta Killin, a German otorhinolaryngologist, used bronchoscope to remove a foreign body from bronchus in 1897 [3]. Often, the inhalation of the foreign body happens for 1-3-year-old children. The reasons for that are as follows. They lack the molar tooth to appropriately grind the food, have little coordination in swallowing, and the height of their larynx is immature. They

Access this article online

Website: www.japer.in

E-ISSN: 2249-3379

How to cite this article: Shohreh Norouzi, Sara Saki, Iman Mohammadi. An unusual long-standing bronchial foreign body (Case report of thumbtack). J Adv Pharm Edu Res 2019;9(S2):128-130.

Source of Support: Nil, Conflict of Interest: None declared.

This is an open access journal, and articles are distributed under the terms of the Creative Commons Attribution-Non Commercial-ShareAlike 4.0 License, which allows others to remix, tweak, and build upon the work non-commercially, as long as appropriate credit is given and the new creations are licensed under the identical terms.

like to investigate the environment by holding objects in their mouth. They are usually running and plying while eating [4]. Sometimes, no sign of a foreign body is observed in the afflicted people and only the chronic symptoms show a hidden foreign body in the lung; the chronic symptoms include cough, repeated infection of the lungs or pneumonia that is not recovered and has no clear history. The hidden foreign body may not be detected for months or years and is often diagnosed mistakenly. In the hearing of a patient with foreign body aspiration, a wheeze sound can be often heard. 21.8% of the patients with foreign body aspiration are afflicted with delay in diagnosis (over thirty days). History, physical and radiological examination, and laboratory tests are often necessary and sufficient for diagnosis. Silvia et al. has reported that the sensitivity and feature of radiological imaging methods for the foreign body aspiration are respectively 73% and 45% [3]. Usually, the sudden incident of wheeze indicates the presence of a foreign body in bronchus, especially when it is one-sided. Sometimes, due to the vegetarian nature (like legumes), the foreign body can swell or cause reaction and inflammation in the surrounding mucus, resulting in complete obstruction and the collapse of the involved lobe. Radiography can be normal in the bronchus foreign bodies, obstructive emphysema can be present as the early symptom, and atelectasis (consolidation) can be present as the late symptom. Even if the history and examination strongly confirm the existence of the foreign body, it is still needed to do the posterior-anterior and lateral chest radiology [5]. Additionally, the image of chest in inhalation and exhalation states would be helpful. Small foreign bodies may not be diagnosed by radiography. Asthma and mucus plug can be similar to the foreign body in radiography. In a study, 35 percent of the people with foreign body had a normal radiography. It is very important to do endoscopy for patients who are skeptic to have a foreign body since negative radiography is not sufficient for rejecting the presence of a foreign body [6]. Removing the foreign body by bronchoscopy is the preferred method for the foreign bodies of chip and bronchus. The size and type of endoscope are selected based on the age of the patient and the location of the foreign body. For children, bronchoscopy is done by general anesthesia in the operation room. Adults may tolerate bronchoscopy at awakening and under anesthesia with lidocaine spray. The equipment must be appropriate and adequate for doing the operation and all of the endoscopy team members should be experienced so as to successfully do the operation. If the hospital is not equipped and the staff is not experienced, the patient needs to be referred to the high-level and more equipped hospitals. Giving steroids and antibiotics to the patient before the operation reduces the complications such as edema and airway infection. Most of the complications are caused because of delay in diagnosis and treatment. Early diagnosis has a direct relationship with reduced complications. The most common place for the foreign body varies based on age [5]. The laryngotracheal foreign bodies lead to major complications in 45% of the cases and 67% of the complications is caused by over-24-hour delays (4). Pneumonia and atelectasis are the

most prevalent complications of removing the foreign body and the treatment by antibiotics and physiotherapy is helpful in these cases. Ekrem has reported a 72-year-old man who has undergone a complete laryngectomy 7 years ago and visited the emergency department for the aspiration of the silicone tracheostomy canola [7]. He used to clean the upper respiratory tract secretion by his finger through tracheostomy. Tola Bayisa reported the aspiration of a pin in an Ethiopian veiled girl [8]. Hashemi reported the aspiration of a knife blade in a 38-year-old young man [9]. Alia Qureshi reported the aspiration of a metal blade in a 22-year-old young man [10]. All of the mentioned cases have been easily observed in radiography. The aspiration case of the present study is a rare one with no sign; the aspirated body is itself a rare case in the studies in the world, too.

Conclusion

The foreign body aspiration may be completely without any sign, especially in the adults. An appropriate history and imaging findings can help us do an accurate diagnosis and treatment.

References

1. Saki N., Nikakhlagh S., Rahim F., Abshirini H. Foreign body aspirations in Infancy: A 20-year experience. *International Journal of Medical Sciences*.2009; 6 (6), pp. 322-328. <https://doi.org/10.7150/ijms.6.322>
2. Saki, N., Rahim, F., Nikakhlagh, S., Saki, G. Meta analysis of the leech as a live foreign body: Detection, precaution and treatment. *Pak J Biol Sci*. 2009 Dec 15;12(24):1556-63. <https://doi.org/10.3923/pjbs.2009.1556.1563>
3. Silvia AB, Muntz HR, Clary R. Utility of conventional radiography in the diagnosis and management of pediatric airway foreign bodies. *Ann Otol Rhinol Laryngol* 1998; 107: 834-838. <https://doi.org/10.1177/000348949810701004>
4. Saki, N., Nikakhlagh, S., Heshmati, S.M. 25-Year Review of the Abundance and Diversity of Radiopaque Airway Foreign Bodies in Children. *Indian Journal of Otolaryngology and Head and Neck Surgery*.2015;Indian J Otolaryngol Head Neck Surg ; 67(3): 261–266. doi: 10.1007/s12070-014-0817-0 <https://doi.org/10.1007/s12070-014-0817-0>
5. Bekele A. Aerodigestive Foreign Bodies in Adult Ethiopian Patients: A Prospective Study at Tikur Anbessa Hospital, Ethiopia. *Int J Otolaryngol*. 2014; pp 1-5 (Article ID 293603)
6. Elkhayat H, Ayyad M. Outcomes of Impaction of Unusual Foreign Bodies in the Aero-digestive Tracts. *J Surg Clin Pract* 2017. 1:1

7. ŞENTÜRK, Serdar ŞEN. An unusual case of foreign body aspiration and review of the literature. *Tüberküloz ve Toraks Dergisi* 2011; 59(2): 173-177 <https://doi.org/10.5578/tt.2134>
8. Seyed Mozafar Hashemi, Mohsen Kolahdouzan, Shahab Shahabi, Hamid Talebzadeh, Mohammad Taghi Rezaei. Foreign Body Aspiration in Adults (Two Unusual Foreign Bodies; Knife and Tube Tracheostomy). *Iranian Journal of Otorhinolaryngology*.2017; Vol.29(1), Serial No.90:59-61
9. Tola Bayisa, Amsalu Bekele, Endale Kassa, Charles Sherman, Jane Carter, Neil Schluger, Otto Schoch. A young woman with an unusual foreign body aspiration. *Ethiop Med J*, 2017, Vol 55, No.4:317-319.
10. Alia Qureshi, Abdollah Behzadi. Foreign-body aspiration in an adult. *Can J Surg*. June 2008; Vol. 51, No. 3:E69-E70. PMID:18682760 PMCid:PMC2496600

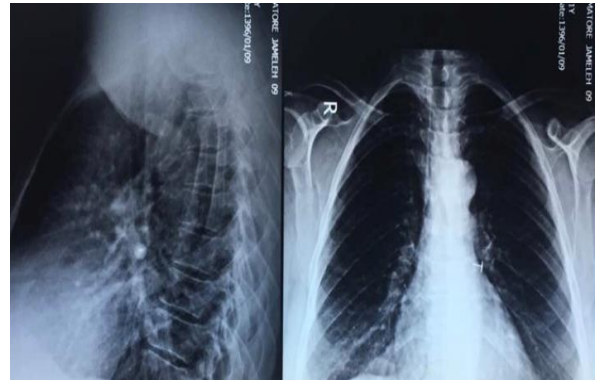


Figure 1. Chest X-ray AP & Lateral show thumbtack foreign body in left bronchus