SPER Publications and Solutions Pvt. Ltd.

Original Article

A cone-beam computed tomography study of the prevalence of two or more canals in mandibular anteriors in the Chennai population

Subhasri Raman[1], V. Jayanth Kumar[2]

[1]Department of Oral Medicine & Radiology, Saveetha Dental College, Saveetha University, Chennai, Tamil Nadu, India, [2]Department of Oral Medicine and Radiology, Saveetha Dental College, Saveetha University, Chennai, Tamil Nadu, India

Correspondence: V. Jayanth Kumar, Department of Oral Medicine and Radiology, Saveetha Dental College, Saveetha University, Chennai, Tamil Nadu, India. E-mail: doctorjayanth@gmail.com

ABSTRACT

The study of root canal anatomy is vital for the success of root canal treatment. The advent of computed tomography (CT) helped in the better understanding of the root canal anatomy. The use of CT entailed a higher radiation and higher cost. The entry of cone-beam computed tomography brought down the cost of imaging and lowering the radiation dose required with a superior resolution. The aim of this study was to study the prevalence of two or more canals in the mandibular anteriors and to check for the bilateral presentation of canal pattern. The study had a sample size of 50 with 32 males and 18 females. The total number of teeth included in the study was 298. The scans were analyzed for the canal anatomy using vertucci classification. The results of the scan revealed the predominant pattern in the mandibular canine was Type I (84% for 43 and 78% for 33) and for the mandibular lateral incisor was Type I (58% for 42 and 44% for 32). The pattern of greater prevalence in mandibular central incisor was also Type I (68 % for 41 and 62% for 31). The results were compared for bilateral presentation of the same type of canal using Pearson correlation analysis. The test yielded statistically significant results ($P < 0.05$). From the above results, it is discernible that only lateral incisors had a tendency for bifid canal. Moreover, the canal morphology was bilaterally symmetrical the teeth across the quadrant.

Keywords: Cone-beam computed tomography, mandibular anteriors, bifid canals, vertucci classification

Introduction

A comprehensive understanding of the root canal anatomy plays a pivotal role in any endodontic procedure. The most common reason for endodontic failure is undoubtedly missed canal anatomy.[1] A successful endodontic treatment stems from locating, cleaning, shaping, and three-dimensional (3D) obturation of the entire canal system. In the past, dentists relied on conventional radiography and studied the dentin map assessing tooth morphology and other relatively unpredictable techniques to achieve a clear understanding of root canal anatomy and morphology. Most of these techniques have been hallmarks of endodontic treatment and have yielded successful results. The modified canal staining and tooth clearing were considered as gold standards. The evolution of computerized tomography (CT) in the recent past has revolutionized dentists to use enhanced radiology techniques for identifying canal anatomy and morphology. Although CT has been available for a fairly decent time, the usage of CT had been limited for the fact that the patients are subjected to a significant amount of radiation. The advent of cone-beam computed tomography (CBCT) had brought in a significant reduction in radiation exposure and affordability of CT in many dental institutions and practices.[2] CBCT obtains a cone-based volume of data which can be analyzed using appropriate software three-dimensionally in the axial, sagittal, and coronal planes. The images can be assessed and stored using a software viewer with a reasonable degree of resolution.[3] This allows preendodontic assessment of root canal anatomy and morphology three-dimensionally giving the dentist accurate information to explore the pulp chamber and identify all canals. This diagnostic aid reduces the risk of canal perforation, missed canal anatomy, or morphology and greatly increases the chances for endodontic success.[4,5] CBCT scanning has observed to be more accurate than traditional conventional and digital radiographs in determining root canal morphology. CBCT scanning can also be used *in vivo* in diagnosis and pre-operative assessments.[6-10] Although there are several literatures on tooth morphology and anatomy using CBCT, studies on local populations are few. The aim of our study is to report on the prevalence of two or more canals in mandibular anteriors in South Indian populations. As a secondary objective, we had also screened for

Access this article online	
Website: www.japer.in	**E-ISSN:** 2249-3379

How to cite this article: Raman S, Kumar VJ. A cone-beam computed tomography study of the prevalence of two or more canals in mandibular anteriors in the Chennai population. J Adv Pharm Edu Res 2017;7(2):92-95.

Source of Support: Nil, **Conflict of Interest:** None declared..

the bilateral symmetrical presentation of the same type of canal in the mandibular anterior region. This is one of the first studies examining bilateral symmetrical presentation of the same type of canal in the mandibular anterior region.

Materials and Methods

The archived CBCT data for a total number of 50 patients residing in Chennai were obtained from the Department of Oral Medicine and Radiology of Saveetha Dental College. The images were taken from patients for several reasons such as 3D cephalometrics, impaction, and assessment. Patients included in the study had almost all the six mandibular anterior teeth, namely, the incisors and canine. The teeth included in the study were free of pathology with intact crowns. The scans were obtained using Orthophos XG 3D, Sirona, Germany, Dentsply Sirona. The scans were obtained with a field of view of 8 cm ×8 cm, 400 µ voxel size, 90 kvp, 8–12 ma, and 10–14 s. The data were analyzed in Galileos software viewer (ver 1.9), Germany, Dentsply Sirona, to identify the number of roots, the number of canals in each root and the configuration of variant canal anatomy (if any) in these teeth. The teeth were analyzed following the vertucci classification [Figure 1].[2,3]

The data were then tabulated and statistically analyzed using Statistical Package for Social Sciences ([SPSS] software), Ver 22, Armonk, NY, IBM Corp. Chi-square analysis in SPSS software was performed for statistical significance.

Results

The study had 50 archived scans from 32 males and 18 females [Table 1]. The scans included in the study were of good diagnostic quality and free of distortions. All the teeth from 43 to 33 were evaluated using vertucci's criteria. A total of 298 teeth were evaluated. There were two scans which had a missing 43 and missing 33.

On evaluating 43, the predominant pattern was Type I with a prevalence of 84% and the predominant pattern in 33 was Type I with a prevalence of 78% [Table 2]. Thus, from the data, it is evident that the canines had a single canal presenting predominantly.

The assessment of 42 and 32 revealed that there was nearly an equal predilection of Type I (unbranched) and Type III, V (bifid) canals. Further, in the case of 32, there was one case with a unique Type V presentation too [Table 3].

The examination of 41 showed the predominant pattern as Type I with a prevalence of 68% while for 31 the predominant pattern was Type I with 64% [Table 4].

The results were then assessed to check if the same type of canal pattern was presenting bilaterally on the corresponding tooth in both the quadrants. The statistical analysis was performed using Pearson correlation, and it was found that the same pattern was presenting bilaterally with a $P < 0.05$ (accepting the null hypothesis that there exists no difference between the sides). A subsequent graphical analysis was performed to see the predominant pattern in each tooth [Figure 2].

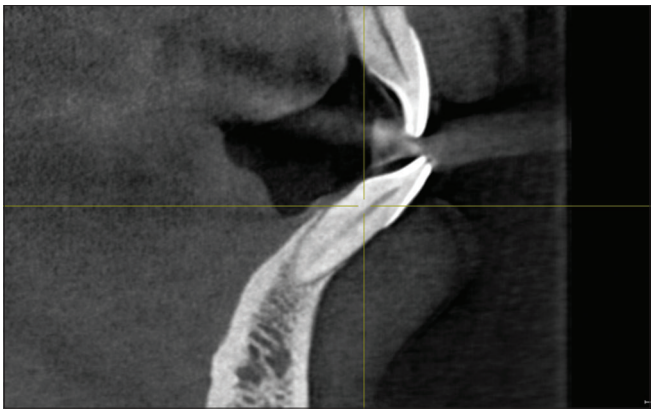

Figure 1: Vertucci classification Type 1 (1)

Table 1: Distribution of samples according to gender

Gender	No. of samples (%)
Male	32 (64)
Female	18 (36)
Total	50 (100)

Table 2: The incidence of root canal systems in tooth 43 and 33

Tooth Pattern	Frequency (%)	
	Tooth 43	Tooth 33
Type I (1)	42 (84)	39 (78)
Type III (1-2-1)	7 (14)	10 (20)
Missing tooth	1 (2)	1 (2)
Tooth	50 (100)	50 (100)

Table 3: The incidence of root canal systems in tooth 42 and 32

Tooth pattern	Frequency (%)	
	Tooth 42	Tooth 32
Type I (1)	29 (58)	22 (44)
Type III (1-2-1)	21 (42)	27 (54)
Type V (1-2)	0 (0)	1 (2)
Tooth	50 (100)	50 (100)

Table 4: The incidence of root canal systems in tooth 41 and 31

Tooth pattern	Frequency (%)	
	Tooth 41	Tooth 31
Type I (1)	34 (68)	31 (62)
Type III (1-2-1)	15 (30)	18 (36)
Type V (1-2)	1 (1)	1 (2)
Tooth	50 (100)	50 (100)

From the graph, it is clear that Type I (unbranched canal) represents the most common pattern in the canines, while the lateral incisors have the Type III pattern presenting predominantly.

Discussion

In clinical practice, the primary reason for failure in the endodontic treatment of permanent mandibular anterior is the inability to locate

variations in the canal. According to the present study, there was a significant prevalence of bifid canals. This is in accordance to the study conducted in various other populations such as Chinese[11] and Iran populations.[12]

According to the present study, Type I and Type III canal morphology were predominant in the [Figures 3 and 4] mandibular anteriors this is in accordance to previous studies.[13,14] And also, the least prevalent was Type V this is similar to the previous literature. The evaluation of mandibular anterior teeth and variations in their root number, number of canals per root, and root canal configuration are a very important part of the endodontic treatment of these teeth. The mandibular anterior teeth present considerable variation in the number of canals per root as well as the canal configuration in the case of multiple canals

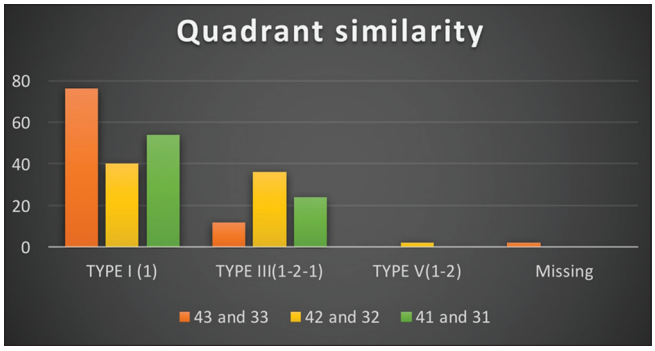

Figure 2: Predominant pattern in each tooth

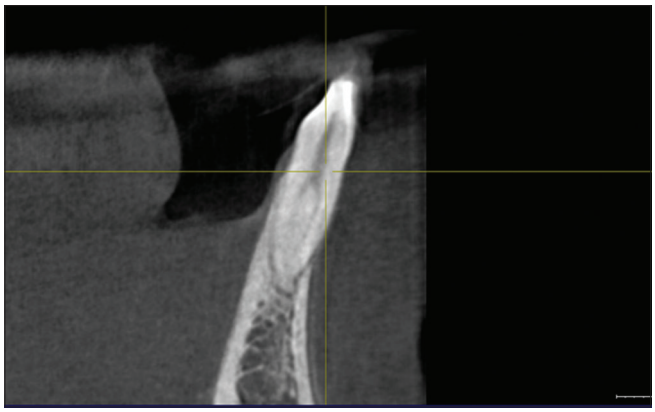

Figure 3: Vertucci classification Type III (1-2)

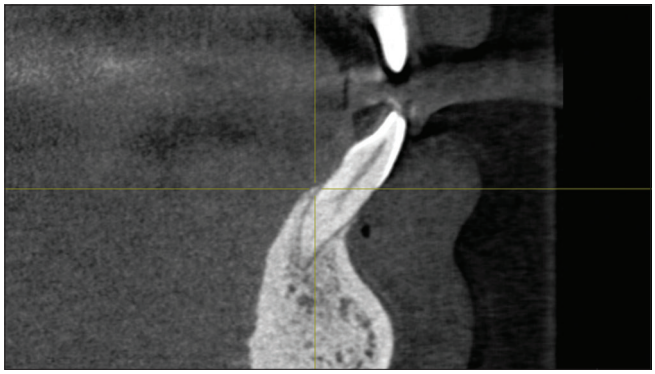

Figure 4: Vertucci classification Type V (1-2)

in a root which is often missed during locating canals. In the past, the assessment was primarily based on the knowledge of the occlusal anatomy, coronal shape, or tooth size.

Radiographic images either included digital or conventional taken at multiple angles to show variations in the number of roots or the number of the canal in each root. Occasionally, root morphology could be studied on a radiograph to provide more information. The real challenge arises while studying canal configuration as most radiographic aids tended to be two-dimensional. With the advent of CBCT, however, it has become possible to evaluate these teeth with relatively noninvasive means and yet obtain a 3D image of the tooth. Unlike CT scans, CBCT has reduced acquisition time and uses lower irradiation doses. Their field of view is limited, but the spatial resolution is good in all planes.[15] CBCT is widely used in implantology and maxillofacial reconstruction; this approach is also used in endodontic diagnosis in cases requiring surgical endodontics and for evaluating canal preparation, obturation, and root filling removal. A recent study reported that CBCT was as precise as the modified canal staining and tooth clearing method in determining root canal morphology.[16] The main advantages of CBCT imaging are its nondestructive in nature. And also, in CBCT images can be studied using different representations (multiplanar reformation, 3D surface rendering). They can be rotated in any spatial plane without superposition of the anatomic structures.

Conclusion

As a result, CBCT offers extensive ability to analyze a tooth resulting in very accurate assessment of all aspects of root and root canal morphology. The present study shows a significant variation that exists in Chennai population attending the Department of Oral Radiology in a Dental College and Hospital. However, the limitations of the study were the small size and ethnics, gender variations could not be assessed. Thus, the study makes a case for routine assessment of teeth such as mandibular anterior teeth by CBCT techniques given the advantages offered by these techniques in the treatment of these teeth. Being prepared for the root canal anatomy and morphology that a treating dentist is about to encounter offers extensive advantages for treatment outcomes. The clinician must have a thorough understanding of normal anatomy and of its variations along with knowledge on interpreting CBCT's resulting in minimal treatment complications such as perforations, ledging, or transportation of root canals. This can directly affect success rates of endodontics as any endodontist can only be better prepared to treat what he can see in advance.

Acknowledgment

We would like to thank the Department of Oral Medicine, Radiology, and Special Care Dentistry for providing is with the permission to access the archives of the CBCT scans.

References

1. Grossman IL, Oliet S, Del Rio E. Endodontic Practice. 11th ed. Philadelphia, PA: Lea and Fabringer; 1988. p. 145-51.

2. Scarfe WC, Farman AG, Sukovic P. Clinical applications of cone-beam computed tomography in dental practice. J Can Dent Assoc 2006;72:75-80.
3. Patel S, Horner K. The use of cone beam computed tomography in endodontics. Int Endod J 2009;42:755-6.
4. Gaurav V, Srivastava N, Rana V, Adlakha VK. A study of root canal morphology of human primary incisors and molars using cone beam computerized tomography: An *in vitro* study. J Indian Soc Pedod Prev Dent 2013;31:254-9.
5. Altunsoy M, Ok E, Nur BG, Aglarci OS, Gungor E, Colak M. A cone-beam computed tomography study of the root canal morphology of anterior teeth in a Turkish population. Eur J Dent 2014;8:302-6.
6. Nair MK, Nair UP. Digital and advanced imaging in endodontics: A review. J Endod 2007;33:1-6.
7. Peters OA, Laib A, Rüegsegger P, Barbakow F. Three-dimensional analysis of root canal geometry by high-resolution computed tomography. J Dent Res 2000;79:1405-9.
8. Mozzo P, Procacci C, Tacconi A, Martini PT, Andreis IA. A new volumetric CT machine for dental imaging based on the cone-beam technique: Preliminary results. Eur Radiol 1998;8:1558-64.
9. Matherne RP, Angelopoulos C, Kulild JC, Tira D. Use of cone-beam computed tomography to identify root canal systems *in vitro*. J Endod 2008;34:87-9.
10. Neelakantan P, Subbarao C, Ahuja R, Subbarao CV, Gutmann JL. Cone-beam computed tomography study of root and canal morphology of maxillary first and second molars in an Indian population. J Endod 2010;36:1622-7.
11. Zhengyan Y, Keke L, Fei W, Yueheng L, Zhi Z. Cone-beam computed tomography study of the root and canal morphology of mandibular permanent anterior teeth in a Chongqing population. Ther Clin Risk Manage 2016;12:19-25.
12. Mirzaie M, Zaban PT, Mohammadi V. Cone-beam computed tomography study of root canals in a Hamadani population in Iran. Avicenna J Dent Res 2012;4:25-31.
13. Lin Z, Hu Q, Wang T, Ge J, Liu S, Zhu M, *et al*. Use of CBCT to investigate the root canal morphology of mandibular incisors. Surg Radiol Anat 2014;36:877-82.
14. Liu J, Luo J, Dou L, Yang D. CBCT study of root and canal morphology of permanent mandibular incisors in a Chinese population. Acta Odontol Scand 2014;72:26-30.
15. Hashimoto K, Arai Y, Iwai K, Araki M, Kawashima S, Terakado M. A comparison of a new limited cone beam computed tomography machine for dental use with a multidetector row helical CT machine. Oral Surg Oral Med Oral Pathol Oral Radiol Endod 2003;95:371-7.
16. Winter AA, Pollack AS, Frommer HH, Koenig L. Cone beam volumetric tomography versus medical CT scanners. NY State Dent J 2005;71:28-33.