

Intramuscular arteriovenous malformation of masseter - A case report

Archana Venugopal, T. N. Uma Maheswari, Jayanth Kumar

Department of Conservative Dentistry and Endodontics, Saveetha Dental College, Saveetha University, Chennai, Tamil Nadu, India

Correspondence: T. N. Uma Maheswari, Department of Oral Medicine and Radiology, Saveetha Dental College, Saveetha University, 162 Poonamallee High Road, Chennai, Tamil Nadu - 600077, India. E-mail: umasamsi@gmail.com

ABSTRACT

The diagnosis of vascular lesion is a challenge to the physician. The management of the vascular lesion depends largely on the diagnosis and the assessment of its morbidity. Arteriovenous malformation (AVM) arises from the persistent of AV anastomosis into the adult life. Hemangiomas are incompletely differentiated endothelial cells during embryogenesis. The case report provides an insight into differentiating an AVM from hemangioma.

Keywords: Vascular lesion, arteriovenous malformation, vascular lesions of head and neck

Introduction

Vascular anomalies in the head and neck region are rare and constitute <1% of all lesions.^[1] The diagnosis of vascular anomalies and their management is still an enigma to the dentist. The understanding of vascular anomalies has undergone tremendous changes over the years. Until the 1980's, all vascular anomalies were referred to as hemangiomas.^[2] Later, the vascular anomalies were classified as hemangiomas and arteriovenous malformations (AVMs).^[3]

Hemangiomas arise as a result of the failure of differentiation of the endothelial cells in the early stages of embryogenesis.^[3] They appear at birth and has a tendency to regress with the growth of the individual. Hemangiomas are subtypes as intraosseous hemangiomas and the more common extraosseous (peripheral) hemangiomas. The intraosseous hemangiomas originate centrally within the bone and grow peripherally to the periosteum. The peripheral hemangiomas originate in the

vessels of the periosteum and grow centrally.^[4]

AVM arise from embryonic changes arising in the late stages of embryogenesis resulting in the persistence of artery venous anastomoses into the adult life from the embryonic life.^[5]

The malformations may be made of capillary, lymphatic, venous, arterial, or mixed types.^[6] The AVM present themselves as high flow or slow flow defects. They have a tendency to cause significant morbidity and rarely fatal uncontrolled hemorrhages. The periphery AVMs have a tendency to occur around puberty or adolescence and cause significant cosmetic and functional disturbance. In the head and neck region, they occur in and around the oral cavity, airway, and muscles with a tendency to cause a space-occupying lesion distorting normal anatomical planes with cosmetic and functional disturbance. The cardinal point of difference between the AVMs and hemangiomas is that unlike hemangiomas, AVMs do not have a tendency to regress and persist well into the adult life of the individual.^[1] AVMs are most commonly seen in the women for reasons unknown.^[4]

The clinical presentation of AVMs is usually asymptomatic with a soft-tissue swelling and a bluish discoloration when the lesion is present close to the mucosa, mobility of teeth, displacement of the mandibular nerve canal.^[7] Occasionally, the lesions have a tendency to present with a bruit accompanied by thrill and neurosensory deficit.^[1]

The imaging of the lesion is best done with a contrast-enhanced computed tomography (CECT) and magnetic resonance

Access this article online

Website: www.japer.in

E-ISSN: 2249-3379

How to cite this article: Venugopal A, Maheswari TNU, Kumar J. Intramuscular arteriovenous malformation of masseter - A case report. *J Adv Pharm Edu Res* 2017;7(3):329-332.

Source of Support: Nil, **Conflict of Interest:** None declared

This is an open access journal, and articles are distributed under the terms of the Creative Commons Attribution-Non Commercial-ShareAlike 4.0 License, which allows others to remix, tweak, and build upon the work non-commercially, as long as appropriate credit is given and the new creations are licensed under the identical terms.

imaging (MRI).^[6] On a non-contrast CT, the lesion presents as an isodense mass in synchrony with a muscle. On a post-contrast IV injection, the lesion appears hyperdense, and the feeder vessels can be identified.^[7] MRI shows the lesion as a hyperintense signal on T2-weighted images which increase in intensity post-contrast.^[4]

In addition, digital subtraction angiography can be used to identify the feeder vessels that helps in treatment planning.^[4]

Once the diagnosis is confirmed the ideal therapy should have the following objectives:

1. Completely eliminating the vascular lattice.
2. Allow somatic growth in the place of the vascular anomaly.

The earliest approach of the surgical excision or ligation of the external carotid artery has now been abandoned, and the current preferred approach is super selective embolization with endovascular techniques.^[8] Recent literature reports the use of isobutylene cyanoacrylate which shows promising results in creating regeneration of tissues.^[9]

Case Report

A 17-years-old male patient reported to the outpatient department with a complaint of progressive painless slow-growing swelling in the left malar prominence region of the face since birth. The patient desired correction of his facial asymmetry. History revealed that the swelling increases in the size in the supine position and while bending down. There is a reduction in the size of the swelling in an erect position. General examination and review of systems revealed no remarkable findings. Past medical and personal history revealed no significant association with the swelling.

On clinical examination extraorally, single diffused swelling with irregular margins was present in the left zygomatic region. The swelling is irregular in shape extending anteriorly 1 cm from the ala of the nose, posteriorly extends up to the tragus of the ear. Superiorly, from infraorbital margins to 1 cm above the inferior border of the mandible. The swelling becomes more prominent on clenching the molar teeth and then disappears. The color of the swelling was normal skin color with smooth surface free from secondary changes and inflammatory changes. There was no visible discharge, pulsation, pigmentation, and scar formation. On palpation, the swelling was non-tender, soft in consistency, compressible, and reducible, and mild pulsation was normal [Figure 1].

As the swelling was present since birth with a positive history of prominence of swelling on bending and is soft, compressible, reducible, and pulsatile in nature suggestive of congenital vascular swelling.

The patient was subjected to orthopantomogram, which revealed multiple radiopacity with radiolucency center giving bull's-eye appearance suggestive of multiple phleboliths in the

left mandibular ramus region [Figure 2]. Ultrasonography shows slow venous flow in the cystic areas. CECT of face and neck revealed a soft-tissue lesion with cystic areas noted in the anterior of left maxilla in the region of masseter [Figure 3]. 4–5 specks of calcification noted within the lesion. On IV contrast, the lesion shows mild enhancement. The lesion measures approximately 6.2 cm × 2.6 cm.

The lesion is present since birth and increased in size and not involuted till the age 19 years. The investigations revealed multiple phleboliths, with slow-filling lesion is suggestive of AVM.

Discussion

The case discussed above had features of a vascular lesion in the form of reducibility, mild pulsations, and further, the lesion was present since birth. The parameter of the swelling increasing on biting is a feature which signifies that the swelling arose from the muscle plane superficial to the muscle. The vascular lesions represent a myriad of entities that arise from disturbance in the endothelial cell network that begins perinatally and progresses into birth. It is here the correct diagnosis of the lesion is essential to differentiate between the lesions to help us plan a proper diagnosis and treatment for the patient. The discussion to follow enlists the salient features of AVMs followed by the unique features of the case reported.

Our understanding and knowledge of vascular lesions have had an interesting course. Earlier the diagnosis was confirmed only on histopathological grounds. However, the path-breaking work of Mullicken and Glowacki had resulted in a paradigm shift in our understanding of the concept.^[10]

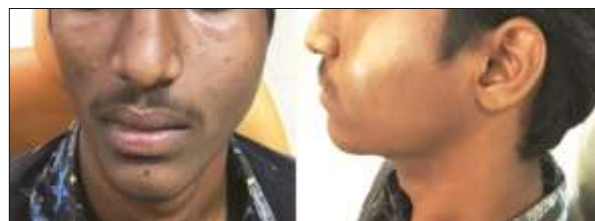

Figure 1: Reveals facial asymmetry with swelling on the left malar region of the face

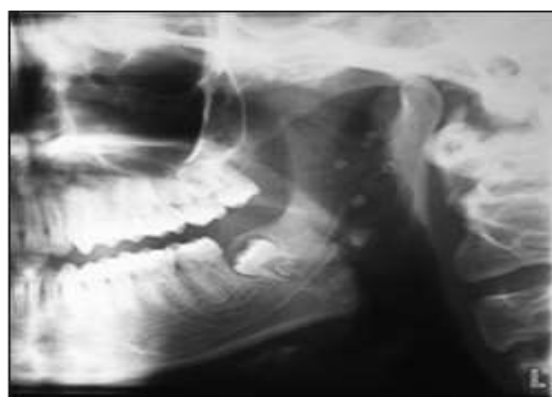

Figure 2: Orthopantomogram reveals multiple phleboliths in the left ramus region

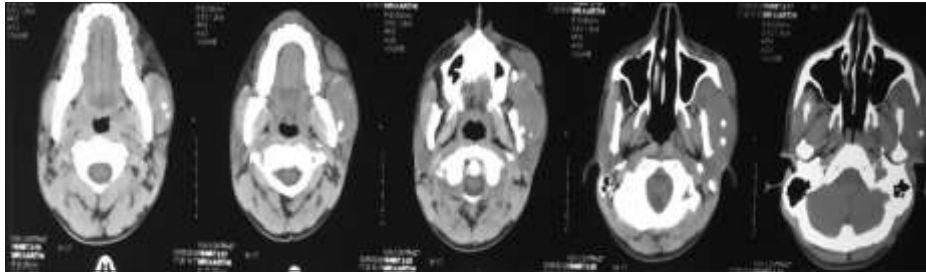


Figure 3: Contrast-enhanced computed tomography shows axial sections shows soft-tissue lesion with cystic areas noted in the anterior of left maxilla in the region of masseter. 4–5 specks of calcification noted within the lesion

It is established that hemangiomas arise from intrinsic proliferation potential of the endothelial cells while AVM's arise by abnormal ectatic proliferations of the blood vessels. There is a tendency for the hemangiomas to involute with the growth of the individual, and the lesion has a tendency to show complete resolution by adolescence of the individual.^[11] On the contrary, AVMs have a tendency to grow during the life of the individual. It is very essential to distinguish between the two lesions as the treatment planning varies significantly between the two lesions.^[12]

The vascular lesions occurring in the maxillofacial region has been pretty rare in a study conducted in a dental hospital reveals that both hemangiomas and AVM's together accounted only for 6.4% of all mucosal lesions occurring in the head and neck region.^[10] There are some reports pointing out that the prevalence reported by some authors had exceeded more than 50%.^[4] However, closer scrutiny of several literatures has revealed that there is variation in the occurrence of vascular lesions based on the age of the individual. Further, those studies have included the occurrence of vascular varix also into the vascular lesions. Hence, when the prevalence of AVMs alone is considered, >50% of the lesions are diagnosed within the first and second decades of life.^[13,14] The work of Al-Khateeb *et al.* reported that the diagnosis of AVMs accounted for only 0.5% of the lesions in children under 5 years and in people up to 20 years the prevalence increased to 5.4%.^[15]

The various studies have pointed an increased occurrence of AVM's in females.^[15-18] The reported male-to-female ratio has ranged from 2:1 to 4:1 in favor of females.^[15,18] The probable reason for this variation as attributed by the authors has been the estrogen has a role to play in the proliferation of endothelial cells.^[18] The role of estrogen thus proves to have a role in the possible future therapeutic application in the treatment of the disease.^[19]

Imaging plays a pivotal role in the diagnosis of the vascular lesions. The imaging plays a key role in identifying the exact plane and location of the lesion. Further, it also helps in identification of the feeder vessels to the lesion.

In our patient, the features of a slow-growing lesion which had progressively increased in size with faint pulsatile nature and having a tendency to increase in size on lying down increase the probability of a vascular lesion. The patient was in the second decade of life which again increases the probability for an AVM. The presence of phlebolith within the lesion increases the favor for a long-standing lesion. The CECT reveals the presence of increased enhancement suggesting a fluid-filled lesion. All these features make the case documentable in favor of a vascular lesion.

References

1. Lakkasetty YT, Malik S, Shetty A, Nakhaei K. Multiple vascular malformations in head and neck-rare case report. *J Oral Maxillofac Pathol* 2014;18:137-42.
2. Kula K, Blakey G, Wright JT, Terry BC. High-flow vascular malformations: Literature review and case report. *Pediatr Dent* 1996;18:322-7.
3. Glowacki J, Mulliken JB. Mast cells in hemangiomas and vascular malformations. *Pediatrics* 1982;70:48-51.
4. Sepulveda I, Spencer ML, Platin E, Trujillo I, Ulloa SN. Intraosseous hemangioma of the Mandible: Case Report and review of the Literature. *Int J Odontostomat* 2013;7:395-400.
5. Mosnier I, Derhy S, Martin F, Princ G. Arteriovenous malformation of the mandible. Apropos of a case in a 6-year-old child. *Ann Otolaryngol Chir Cervicofac* 1996;113:434-9.
6. Richter GT, Friedman AB. Hemangiomas and vascular malformations: Current theory and management. *Int J Pediatr* 2012;2012:645678.
7. Aldridge E, Cunningham LL Jr, Gal TJ, Yepes JF, Abadi BJ. Intraosseous venous malformation of the mandible: A review on interdisciplinary differences in diagnostic nomenclature for vascular anomalies in bone and report of a case. *J Oral Maxillofac Surg* 2012;70:331-9.
8. Kondylidou-Sidira A, Dietrich E-M, Koloutsos G, Sakkas L, Antoniadis K. Intraosseous vascular malformation of the mandibular condyle: Presentation of a case and differential diagnosis. *Oral Radiol* 2012;28:150-6.

9. Oliveira GG, García-Rozado A, Rey RL. Intraosseous mandibular hemangioma. A case report and review of the literature. *Med Oral Patol Oral Cir Bucal* 2008;13:E496-8.
10. Mulliken JB, Glowacki J. Hemangiomas and vascular malformations in infants and children: A classification based on endothelial characteristics. *Plast Reconstr Surg* 1982;69:412-22.
11. Noreau G, Landry PP, Morais D. Arteriovenous malformation of the mandible: Review of literature and case history. *J Can Dent Assoc* 2001;67:646-51.
12. Rodesh G, Soupre V, Vazquez M, Fain J, Alvarez H, Lasjaunais P. Malformations arterioveineuses maxillomandibulaires. Place du traitement endovasculaire. A propos de 14 cas. *Rev Stomatol Chir Maxillofac* 1999;100:293-8.
13. Jankittivong A, Aneksuk V, Langlais RP. Oral mucosal conditions in elderly dental patients. *Oral Dis* 2002;8:218-23.
14. Paltiel HJ, Burrows PE, Kozakewich HP, Zurakowski D, Mulliken JB. Soft-tissue vascular anomalies: Utility of US for diagnosis. *Radiology* 2000;214:747-54.
15. Al-Khateeb T, Al-Hadi Hamasha A, Almasri NM. Oral and maxillofacial tumours in north Jordanian children and adolescents: A retrospective analysis over 10 years. *Int J Oral Maxillofac Surg* 2003;32:78-83.
16. Barrett AW, Speight PM. Superficial arteriovenous hemangioma of the oral cavity. *Oral Surg Oral Med Oral Pathol Oral Radiol Endod* 2000;90:731-8.
17. Donnelly LF, Adams DM, Bisset GS rd. Vascular malformations and hemangiomas: A practical approach in a multidisciplinary clinic. *AJR Am J Roentgenol* 2000;174:597-608.
18. Jackson IT, Carreño R, Potparic Z, Hussain K. Hemangiomas, vascular malformations, and lymphovenous malformations: Classification and methods of treatment. *Plast Reconstr Surg* 1993;91:1216-30.
19. Seehra J, Coulthard P. Arteriovenous malformation of the mandible- A case report. *Br Dent J* 1965;3:55-76.