

The effect of Calcium channel blocker in the Betamethasone-induced Glaucoma model in rabbits

Waleed K. Abdulsahib^{1*}, Sattar J. Abood¹

¹Pharmacology and Toxicology Department, College of Pharmacy, Al- Farahidi University, Baghdad, Iraq.

Correspondence: Waleed K. Abdulsahib, Pharmacology and Toxicology Department, College of Pharmacy, Al- Farahidi University, Baghdad, Iraq. 10070. waleed.abdulsahib@alfarahidiuc.edu.iq; waleedkalel22@yahoo.com.

ABSTRACT

To Evaluate the Ocular-hypotensive Effect of Levamlodipine in the Betamethasone- induced Glaucoma Model in the Rabbits. Ocular-hypertension was made by weekly subconjunctival injection of Celestone Chronodose® for four weeks in the right eye and the left eye was left as a control. The animals were divided into three groups, twice-daily eye drops of Levamlodipine 0.25%, Levamlodipine 0.5 %, and Timolol maleate 0.5% were administered to groups 1, 2, and 3 respectively (n = 6 for each group) for 12 days after week 4 of induction. All left eyes (control) administered sterile distilled water (DW) twice daily.

The subconjunctival administration of corticosteroid weekly after four weeks creates a significant ($p < 0.001$) increment in IOP in right eyes in groups 1, 2, and 3. Levamlodipine 0.25% shows a significant decrease in IOP after 3 days ($p < 0.001$), reaching 23.31 ± 0.56 mmHg. Group 2 that administered 0.5% Levamlodipine, IOP significantly reduced ($p < 0.001$) (from 23.93 ± 0.61 mmHg to 20.93 ± 0.76 mmHg). Levamlodipine 0.5% produced a significant ($p < 0.001$) drop in the IOP when compared to Levamlodipine 0.25% and Timolol 0.5 in days 6, 9 and 12. During the study period, no systemic adverse events were observed in the left and right eyes of all groups. Levamlodipine has a promising beneficial effect in reducing intraocular pressure in the chronic model of glaucoma.

Keywords: Betamethasone, Levamlodipine, Glaucoma, Timolol

Introduction

Glaucoma is a complex disorder with several components that participate in its progression. A significant factor of optic nerve damage in glaucoma is increased Intraocular Pressure (IOP) [1]. If the treatment of elevated and IOP is not adequate, it may lead to progressive blindness. Parasympathomimetic drugs, β -adrenergic receptor antagonists, inhibitors of carbonic anhydrase enzyme, an agonist of the $\alpha 2$ -adrenergic receptor, prostaglandin analogs, and inhibitors of the angiotensin-converting enzyme are some drugs used for controlling glaucoma [2-4].

The golden choice in the treatment of glaucoma is Timolol eye drops. Nevertheless, Timolol is recognized to reach the systemic circulation and cause different side effects [5]. While glaucoma is considered to be a serious chronic eye condition, there is still no perfect agent to be used for this disease, and there has been a constant urge for new drugs to be discovered [6].

Calcium is an essential intracellular messenger and Ca^{2+} inflow can have many effects on

dynamics of aqueous humor, including osmotic, ciliary and hydrostatic components [7, 8]. Commonly used to treat hypertension and coronary artery disease, Calcium Channel Blockers (CCBs) decrease blood vessel tone by suppressing the Ca^{2+} entrance, inducing vasodilation, and accelerating blood flow in many tissues, including the head of the optic nerve [9]. The synthesis of extracellular matrix collagen protein may also be inhibited by CCBs, indicating beneficial effects on glaucoma [10]. CCB relaxes the trabecular meshwork cells by inhibiting the L-type channel located in the retina of the eye, thereby improving the outflow facilities of aqueous humor [11]. In the dissected eyes of humans, perfusion studies displayed a dose-

Access this article online

Website: www.japer.in

E-ISSN: 2249-3379

How to cite this article: Abdulsahib WK, Abood SJ. The effect of Calcium channel blocker in the Betamethasone-induced Glaucoma model in rabbits. J Adv Pharm Educ Res. 2021;11(1):135-40. <https://doi.org/10.51847/2d3w8vfSVt>

This is an open access journal, and articles are distributed under the terms of the Creative Commons Attribution-Non Commercial-ShareAlike 4.0 License, which allows others to remix, tweak, and build upon the work non-commercially, as long as appropriate credit is given and the new creations are licensed under the identical terms.

related rise in the drainage facility later to topical CCBs administration [12]. Levamlodipine is the Amlodipine active enantiomer, and familiar as S-amlodipine. Receptor-binding experiments have shown that (S)-enantiomers can attach to L-type calcium channels and block the Ca^{++} influx, unlike the (R)-enantiomer. New research indicates that Levamlodipine can block calcium entrance from transmembrane into the cardiovascular smooth muscle cells, resulting in dilation of vessels and thus a decrease in the pressure of the blood [13]. In the current study, we inspected the hypotensive role of Levamlodipine in the chronic model of glaucoma in the rabbit eyes that was induced by subconjunctival injection of betamethasone.

Experimental animals

Male and female New Zealand white rabbits weighing about 1.6-2.5 kg were housed under suitable environments: humidity, $45 \pm 4\%$, temperature, 25 ± 3 C, and 12-hour light/12-hour dark cycle, animals were easily convenient arrival to food and water. The protocol of the study was accepted by the Institutional Animal Ethical Committee of Pharmacy College, Al Farahidi University.

Materials and Methods

The protocols of the experimental and holding were directed in agreement with the (ARVO) Association for Research in Vision and Ophthalmology Statement. A total of 18 albino rabbits, aged 4 months of both sexes were used in this study. All IOP measurements were obtained with Schiotz tonometer (Biro, Germany) after rabbits anesthetizing through marginal ear vein with (0.5 mg/kg) intravenous Midazolam. Furthermore, eyes anesthetize with topical proparacaine hydrochloride (Alcone) before each IOP measurement. For each IOP measurement, an average of three readings is used. Induction of elevated IOP was performed using a weekly subconjunctival injection of Celestone Chronodose® (Betamethasone acetate and Betamethasone sodium phosphate, MSD Company) for four weeks in the right eye and left eye left as control [14]. IOP measurements were obtained before and after induction with steroids for both eyes every 3 days and at the same time (11 A.M) to avoid diurnal fluctuation of the IOP. The animals were divided into three groups, twice-daily eye drops of Levamlodipine 0.25%, Levamlodipine 0.5 %, and Timolol Maleate 0.5% were administered to groups 1, 2, and 3 respectively ($n = 6$ for each group) for 12 days after week 4 of induction. All left eyes (control) administered sterile distilled water (DW) twice daily. Levamlodipine 0.25% solution was prepared by diluting 250 mg of Levamlodipine pure powder in 10 ml of distilled water, and

Levamlodipine 0.5% solution was prepared by diluting 500 mg of Levamlodipine pure powder in 10 ml of distilled water.

Statistical analysis

IOP is expressed as mean \pm SD in the tables and as mean \pm SE in the figures. The t-test was used for Intragroup comparisons. One-way variance analysis in SPSS version 23 was used to compare the mean of different groups, followed by a Tuckey post-hockey test. Data considered statistically significant if the 'p' value less than 0.05.

Results and Discussion

The subconjunctival administration of corticosteroid weekly after four weeks creates a significant ($p < 0.001$) increment in IOP in right eyes in group 1 (from 15.36 ± 0.45 mmHg to 24.76 ± 0.47 mmHg), group 2 (from 15.58 ± 0.47 mmHg to 23.93 ± 0.61 mmHg) and group 3 (16.01 ± 0.43 mmHg to 24.8 ± 0.46 mmHg) when compared with pre-induction IOP (**Tables 1-3**).

The right eye (group 1) who received topical treatment with 0.25% Levamlodipine had a significant decrease in IOP after 3 days ($p < 0.001$), reaching 23.31 ± 0.56 mmHg. Besides, a significant ($p < 0.001$) reduction was observed on day 6 (reaching 22.37 ± 0.72 mmHg), day 9 (reaching 19.45 ± 0.37 mmHg), when compared with the induced IOP (24.76 ± 0.47 mmHg). At the same time, the left eyes of group 1 did not show any significant ($p > 0.5$) reduction in the IOP during the time of the experiment, as shown in **Figure 1**.

In group 2, as shown in **Figure 2**, after 3 days of topical administration of 0.5% Levamlodipine, the IOP of the right eye was significantly reduced ($p < 0.001$) (from 23.93 ± 0.61 mmHg to 20.93 ± 0.76 mmHg). Moreover, it is compared with the induced IOP readings, a significant ($p < 0.001$) reduction was observed on days 6, 9, and 12. There was no significant reduction in IOP (control) of the left eye that received DW.

For group 3 (positive control) 0.5% Timolol was administered to the right eye for 3 days that showed a significant decrease in IOP ($p < 0.001$) (from 24.8 ± 0.46 mmHg to 21.1 ± 0.26 mmHg). Besides, compared with the pretreatment IOP, a significant decrease ($p < 0.001$) was observed on days 6, 9, and 12 as shown in **Figure 3**.

Levamlodipine 0.5% produced a significant ($p < 0.001$) drop in the IOP when compared to Levamlodipine 0.25% and Timolol 0.5 on days 6, 9, and 12, as shown in **Figure 4**.

During the study period, no systemic adverse events were observed in the left and right eyes of all groups.

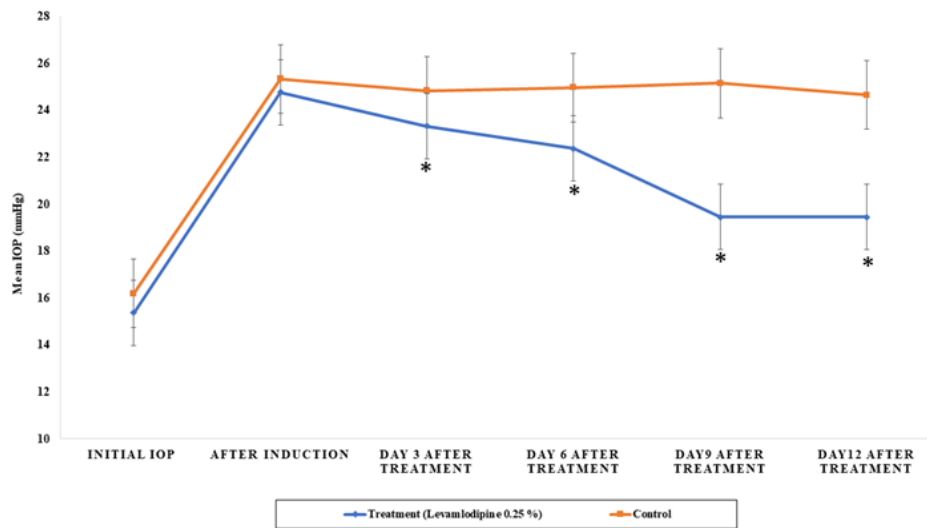


Figure 1. The Effect of Levamlodipine 0.25% on IOP (mmHg) of Betamethasone Induced Glaucoma. Each reading represents the mean IOP \pm SEM of n=6. * Significantly Different from Induction Reading. SEM= Standard Error of the Mean, IOP= Intraocular Pressure

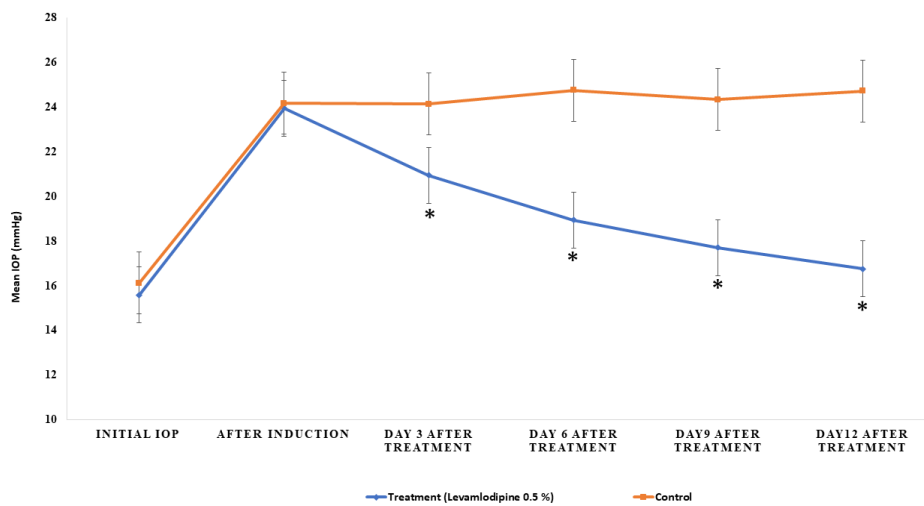


Figure 2. Levamlodipine 0.5% Effect on IOP (mmHg) of Betamethasone Induced Glaucoma. Each reading represents the mean IOP \pm SEM of n=6. * Significantly Different from Induction Reading. SEM= Mean of Standard Error, IOP= Intraocular Pressure

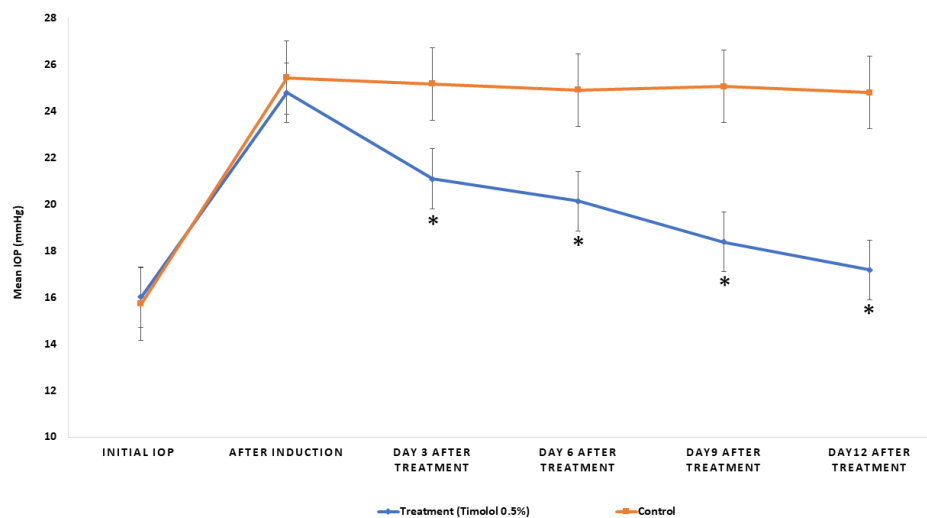


Figure 3. The Effect of Timolol 0.5% on IOP (mmHg) of Betamethasone Induced Glaucoma Each reading represents mean IOP \pm SEM of n=6. * significantly Different from Induction Reading SEM= Standard Error of the Mean, IOP= Intraocular Pressure

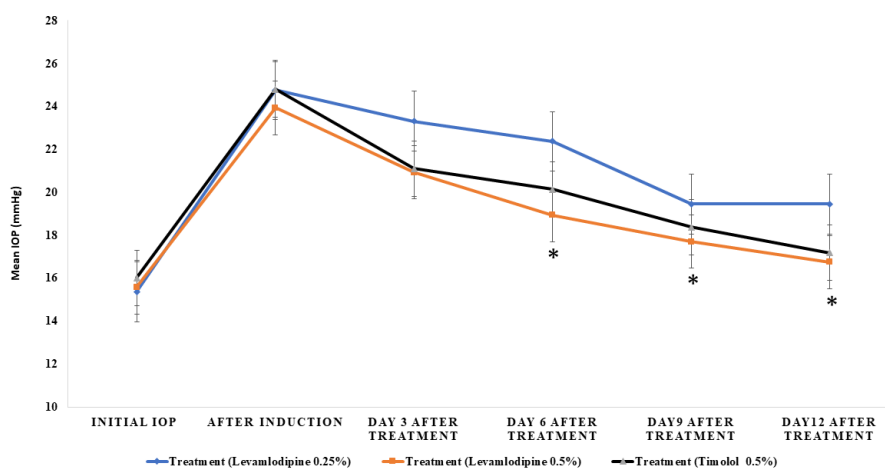


Figure 4. The Effect of Levamlodipine 0.25%, Levamlodipine 0.5 % and Timolol 0.5% on IOP (mmHg) of Betamethasone induced glaucoma. Each reading represents the mean IOP ± SEM of n=6. * Significantly different from Levamlodipine 0.25% and Timolol 0.5%. SEM= Standard Error of Mean, IOP= Intraocular Pressure

Table 1. Mean Intraocular Pressure (mmHg) Represented as Initial, Post Subconjunctival Induction using Betamethasone Injection Weekly for 4 doses, and Post-topical Treatment with Levamlodipine 0.25 %. (n= 6)

	Initial IOP (mmHg)	After Induction	Day 3	Day 6	Day 9	Day 12
Right eye Levamlodipine 25% (Treatment)	15.36 ± 0.45	24.76 ± 0.47	23.31 ± 0.56	22.37 ± 0.72	19.45 ± 0.37	19.4 ± 0.45
Left Eye (Control)	16.2 ± 0.95	25.33 ± 0.48	24.83 ± 0.89	24.96 ± 0.56	25.15 ± 1.1	24.65 ± 1.3

Table 2. Mean Intraocular Pressure (mmHg) Represented as Initial, Post Subconjunctival Induction using Betamethasone Injection Weekly for 4 Doses, and Post-topical Treatment with Levamlodipine 0.5 %. (n= 6)

	Initial IOP (mmHg)	After Betamethasone Induction	Day 3	Day 6	Day 9	Day 12
Right eye Levamlodipine 0.5% (Treatment)	15.58 ± 0.47	23.93 ± 0.61	20.93 ± 0.76	18.93 ± 0.30	17.70 ± 0.33	16.7 ± 0.32
Left Eye (Control)	16.11 ± 0.63	24.15 ± 0.86	24.11 ± 0.51	24.73 ± 0.68	24.31 ± 0.94	24.7 ± 1.05

Table 3. Mean Intraocular Pressure (mmHg) represented as Initial, Post Subconjunctival Induction using Betamethasone Injection Weekly for 4 Doses, and Post-topical Treatment with Timolol 0.5 %. (n= 6)

	Initial IOP (mmHg)	After Betamethasone Induction	Day 3	Day 6	Day 9	Day 12
Right Eye Timolol 0.5% (Treatment)	16.01 ± 0.43	24.8 ± 0.46	21.1 ± 0.26	20.13 ± 0.24	18.38 ± 0.81	17.1 ± 0.67
Left Eye (Control)	15.71 ± 1.4	25.45 ± 1.3	25.18 ± 0.57	24.91 ± 0.44	25.06 ± 0.58	24.8 ± 0.89

Most glaucoma animal models in the previous studies used the normal or low tension IOP to reveal the topical CCBs effects [15]. In the current study, the hypotensive effect of topical Levamlodipine (0.25 and 0.5 percent) on betamethasone-induced ocular hypertension was confirmed (chronic glaucoma model). These findings come following Ganekal *et al.* that used topical Verapamil and Diltiazem for decreasing IOP in the chronic models [16]. Panchal and the team in one experiment using chronic glaucoma models also show a good reduction in the IOP after 2 hours of topical administration of CCBs [17]. Prabhakar and co-workers display a topical administration of Diltiazem 0.5% and verapamil 0.1% decrease the IOP in steroid-induced glaucoma model of rabbits [18]. Furthermore, another

study the Prabhakar shows a good oculo-hypotensive action of orally administered Amlodipine in a patient with IOP of more than 25 mmHg [19]. Additionally, Walced and co-workers show an obvious drop in the IOP of topical Nimodipine in the Betamethasone-induced model of glaucoma [7]. All these studies gave the important message of the important role of calcium receptor in the formation of aqueous humor.

Calcium channel blockers change the concentration of calcium in the cell, which helps to change the flux of calcium on the cell membrane and affects many processes of intracellular signal transmission [20]. Hydrophilic CCBs act primarily on the optic nerves and cornea, while lipophilic CCBs act centrally [21]. In the glutamate pathway, calcium influx is also considered to be

the final step of axon death. Therefore, the capacity to close the influx of calcium will produce a neuroprotective gain [16]. Besides, by inhibiting endothelin-1, CCB can enhance blood flow in the eye [18-21]. Nevertheless, the impact of CCB on IOP stays debatable [22]. Calcium inflows may perhaps have many effects on the dynamics of aqueous humor, which include ciliary body perfusion, a hydrostatic element created by the pressure of the blood, and an osmotic component induced by ciliary epithelium on active sodium, calcium, and other ions secretions [7]. The CCBs affect on ophthalmic blood flow has been discussed by recent studies. Harino *et al.* proved that the flow of the blood in the head of the optic nerve was improved following the intravenous injection of nifedipine in cats using laser Doppler velocimeter and blood flow meter [23]. Netland *et al.* found that local verapamil can reduce the ocular resistance of the blood vessels using color Doppler ultrasound analysis [24]. The positive effects of CCBs on defects of the visual field and contrast sensitivity have also been studied [25]. CCBs play an important role in retinal relaxation leading to improve ocular circulation [26]. The Santafe *et al.*'s study shows that CCBs minimize secretion of aqueous humor [19]. CCB can inhibit the normal formation of aqueous humor through the interference of gap junctions between pigmented epithelial cells and non-pigmented epithelial cells, which will lead to changes in the cell permeability of the ciliary epithelium [17]. The content of cyclic Adenosine Monophosphate (cAMP) in cells of ciliary epithelium can also shift, influencing intraocular pressure by reducing aqueous humor production or increasing outflow facilities [27]. Inactivating calcium channel phosphorylation within the cell membrane, which occurs by inhibition of intracellular calcium absorption, will result in IOP reduction by CCBs [11]. It is well known that the shrinkage characteristics of the trabecular meshwork will be affected by the L-type Ca²⁺ channel. Maximizing the ease of outflow and trabecular mesh cells is also provided by CCBs [28]. The beneficial effect of blocking calcium channels in treating glaucoma can also be attributed to the reduction of vascular resistance, which increases the speed of blood in the capillaries of the optic nerve head [29]. The findings of our research, by previous studies, showed the IOP reduction behavior of the application of topical CCBs [9, 18].

Conclusion

Levamlodipine has a promising beneficial effect in reducing intraocular pressure in the chronic model of glaucoma.

Acknowledgments: None

Conflict of interest: None

Financial support: None

Ethics statement: The protocol of the experiment was approved by the Institutional Animal Ethical Committee of the Pharmacy College, Al Farahidi University under the Number 41420 .

References

1. Alsirhani EK, Ayidh Alosaimi SM, Ali Alkhwajah SA, Alsaqer SK, Alanazi MSH, Alanzi HOH, et al. An Overview of Glaucoma Diagnosis & Management: A Literature Review. *Arch Pharm Pract.* 2020;11(4):66-9.
2. Panchal SS, Mehta AA, Santani DD. Effect of potassium channel openers in acute and chronic models of glaucoma. *Taiwan J Ophthalmol.* 2016;6(3):131-5.
3. Shalaby WS, Shankar V, Razeghinejad R, Katz LJ. Current and new pharmacotherapeutic approaches for glaucoma. *Expert Opin Pharmacother.* 2020;21(16):2027-40.
4. Dhyani A, Kumar G. A New Vision To Eye: Novel Ocular Drug Delivery System. *Pharmacophore.* 2019;10(1):13-20.
5. Yoon DJ, Kaur R, Gallegos A, West K, Yang H, Schaefer S, et al. Repurposing Ophthalmologic Timolol for Dermatologic Use: Caveats and Historical Review of Adverse Events. *Am J Clin Dermatol.* 2020;1-11.
6. Abdulsahib WK, Abood SJ. Effect of digoxin ophthalmic solutions on the intraocular pressure in rabbits. *Drug Invent Today.* 2020;14(1):5-9.
7. Abdulsahib WK, Fadhil OQ, Tizkam HH. Effect of topically applied nimodipine on the intraocular pressure on ocular normotensive and betamethasone-induced hypertensive eyes in rabbits. *Int J Res Pharm Sci.* 2019;10(4):2727-32.
8. Wang J, McDonagh DL, Meng L. Calcium channel blockers in acute care: the links and missing links between hemodynamic effects and outcome evidence. *Am J Cardiovasc Drugs.* 2020;1-15.
9. Nuzzi R, Tridico F. Glaucoma: biological trabecular and neuroretinal pathology with perspectives of therapy innovation and preventive diagnosis. *Front Neurosci.* 2017;11:494.
10. Khawaja A. Calcium channel blockers and risk of primary open-angle glaucoma. *J Glaucoma.* 2019;28(3):e49-50.
11. Abdulsahib WK. Future Therapeutic Strategies in the Glaucoma Management. *J Adv Med Pharm Sci.* 2020;22(7):40-9.
12. Bell JG, Mousavi MPS, Abd El-Rahman MK. Electrochemical sensing of carbachol in ophthalmic solutions. *J Electrochem Soc.* 2018;165(16):B835.
13. Liu J, Li X, Zhang H, Liu Y, Wu M, Niu J, et al. S-amlodipine-bisoprolol combination therapy caused elevated transaminases and triglyceride levels in healthy Chinese subjects: a randomized controlled, open-label, multiple-dose pharmacokinetic interaction study. *Expert Opin Drug Metab Toxicol.* 2019;15(9):687-95.
14. Abdulsahib WK, Al-Zubaidy A, Sahib HB, Kathem SH. Tolerable ocular hypotensive effect of topically applied sildenafil in ocular in normotensive and betamethasone-

- induced hypertensive rabbits. *Int J Pharm Sci Rev Res.* 2015;35(1):96-102.
15. Hussein MQ, Kadim HM, Abdulsahib WK. Effect of Telmisartan on Intra-Ocular Pressure in induced Open Angle Glaucoma in Rabbits. *Int J Sci Res ISSN.* 2017;6(10):1565-661.
16. Ganekal S, Dorairaj S, Jhanji V, Kudlu K. Effect of topical calcium channel blockers on intraocular pressure in steroid-induced glaucoma. *J Curr Glaucoma Pract.* 2014;8(1):15.
17. Panchal SS, Mehta AA, Santani D. Effect of monatepil, a calcium channel blocker in ocular hypertensive rabbits. *Polish Ann Med.* 2017;24(2):171-4.
18. Adake P, Somashekar HS, Gokul CG, Acharya A, Kumar MN, Santosh R. Ocular hypotensive effect of topical verapamil and diltiazem in steroid induced glaucoma model of rabbits. *J Pharm Res Int.* 2013;3(4):1115-26.
19. Adake P, Poornima MS, Somashekar HS, Suranagi P, Jayaraj SG, Patil P. Oculohypotensive effect of oral amlodipine in hypertensive individuals associated with increased intraocular pressure. *Drug Invent Today.* 2013;5(2):71-5.
20. Wu A, Khawaja AP, Pasquale LR, Stein JD. A review of systemic medications that may modulate the risk of glaucoma. *Eye.* 2020;34(1):12-28.
21. Eisenberg MJ, Brox A, Bestawros AN. Calcium channel blockers: an update. *Am J Med.* 2004;116(1):35-43.
22. Gasser P, Flammer J. Short-and long-term effect of nifedipine on the visual field in patients with presumed vasospasm. *J Int Med Res.* 1990;18(4):334-9.
23. Harino S, Riva CE, Petrig BL. Intravenous nicardipine in cats increases optic nerve head but not retinal blood flow. *Invest Ophthalmol Vis Sci.* 1992;33(10):2885-90.
24. Netland PA, Grosskreutz CL, Feke GT, Hart LJ. Color Doppler ultrasound analysis of ocular circulation after topical calcium channel blocker. *Am J Ophthalmol.* 1995;119(6):694-700.
25. Kryshanowskiĭ GN, Kashintseva LT, Mikheĭtseva IN, Lipovetskaia EM, Kopp OP. Cyclic nucleotides in experimental glaucoma. *Biulleten'Eksperimental'noi Biol i Meditsiny.* 1988;106(10):419-21.
26. Osborne NN, Wood JPM, Chidlow G, Casson R, DeSantis L, Schmidt KG. Effectiveness of levobetaxolol and timolol at blunting retinal ischaemia is related to their calcium and sodium blocking activities: relevance to glaucoma. *Brain Res Bull.* 2004;62(6):525-8.
27. Sears M. A mechanism for the control of aqueous humor formation. *Glaucoma Appl Pharmacol Med Treat.* 1984;303-24.
28. Wu A, Khawaja AP, Pasquale LR, Stein JD. A review of systemic medications that may modulate the risk of glaucoma. *Eye.* 2020;34(1):12-28.
29. Kastner A, Montesano G, De Moraes CG, Kang JH, Wiggs J, Pasquale L, et al. Calcium Channel Blocker Use and Risk of Glaucoma in a Large United Kingdom Population. *Invest Ophthalmol Vis Sci.* 2020;61(7):2739.