

Pharmacological combination for awake tracheal intubation in patients with giant struma: A case report

Dewi Yulianti Bisri^{1*}, Radian Ahmad Halimi¹, Reza Widiyanto Sudjud¹, Tatang Bisri²

¹Department Anesthesiology and ICU Medical Faculty Universitas Padjadjaran/Dr. Hasan Sadikin Hospital/Melinda 2 Hospital, Bandung-Indonesia. ²Department Anesthesiology and ICU Medical Faculty Universitas Jenderal Achmad Yani Cimahi-Bandung/Melinda 2 Hospital Bandung-Indonesia.

Correspondence: Dewi Yulianti Bisri, Department Anesthesiology and ICU Medical Faculty Universitas Padjadjaran/Dr. Hasan Sadikin Hospital/Melinda 2 Hospital, Bandung-Indonesia. dewi.yulianti@unpad.ac.id

ABSTRACT

The principle of general anesthesia is a free airway during anesthesia-surgery. A female patient age 55 year, who has morbid obesity with body mass index/BMI 38.6, and suffered from hypertension, diabetes mellitus, and giant struma was having struma-lifting surgery in Melinda 2 Hospital Bandung-Indonesia. The patient was assumed to have difficulties in performing intubation, therefore it was decided to do awake tracheal intubation (ATI) for the general anesthesia facility. Patient was positioned in a Ramped position, she was given monitor standard, was given binasal oxygen, and several medicine which combination of lidocaine spray, lidocaine, fentanyl, midazolam, and dexmedetomidine intravenous. Intubation was done with direct laryngoscopy. After the endotracheal tube (ETT) was entered, which was confirmed by the balloon movement of the anesthesia machine, the patient was given propofol, additional fentanyl, and muscle paralyzed atracurium and dexmedetomidine was stopped. Anesthesia maintenance was N₂O/O₂, sevoflurane. Bleeding amount was 1200 mL and the fluid given was ringer laktat 1000 mL and gelofusin 1000 mL. During the surgery there was severely decreasing blood tension which needed efedrin, then it was replaced with norepinefrin bitartrate monohydrate (vascon) and finally the combination of vascon and dobutamine. At the end of the surgery, after the patient could open her eyes, spontaneous respiration and extubation were given. The post-surgery patient then was taken care of in a high-care unit for four days before she was moved to the ward.

Keywords: Awake tracheal intubation, Giant struma, Morbid obes, Hypertension, Difficult airway, Severe hypotension

Introduction

The principle of general anesthesia is keeping a free airway during anesthesia and surgery [1, 2]. Patients with giant struma and obesity, the main problem is to free the airway when the patient is given anesthesia. Pre-surgery evaluation to see whether the airway is easy to freed or not, including intubation and ventilation difficulties criteria, can be conducted by using the test Look externally, Evaluate the 3-3-2 rule, Mallampati, Obstruction, Neck mobility (LEMON) [3].

A difficult airway is a clinical situation in which a healthcare provider who is skilled at airway management encounters difficulty with one or more standard methods of airway management. The American Society of Anesthesiologists (ASA) defines a difficult airway as existing when "a conventionally trained anesthesiologist experiences difficulty with facemask ventilation of the upper airway, difficulty with tracheal intubation, or both"[4-6].

The difficulty of airway management varies widely and will depend on several factors including patient characteristics, medical and surgical history, airway examination, the necessary clinical context of airway management (including the nature of any planned surgical procedures), and the patient's current status and vital signs [4, 7].

Some international organization namely the American Society of Anesthesiologists (ASA) and Difficult Airway Society (DAS) have proposed procedure to manage difficult airway, which provide basic methods for difficult intubation. It is important for doctors who perform intubation to know how to handle tools and

Access this article online

Website: www.japer.in

E-ISSN: 2249-3379

How to cite this article: Bisri DY, Halimi RA, Sudjud RW, Bisri T. Pharmacological combination for awake tracheal intubation in patients with giant struma: A case report. *J Adv Pharm Educ Res.* 2024;14(2):103-9. <https://doi.org/10.51847/hLw3qroj2W>

This is an open access journal, and articles are distributed under the terms of the Creative Commons Attribution-Non Commercial-ShareAlike 4.0 License, which allows others to remix, tweak, and build upon the work non-commercially, as long as appropriate credit is given and the new creations are licensed under the identical terms.

understand the necessary techniques for successful intubation. As stated in the Closed Claims Analysis performed by the ASA, failed intubation is still becoming the main cause of morbidity and mortality [8-10].

To intubate patients with difficult airway, it is better to perform it when the patient is awake therefore he/she can breath spontaneously. Awake tracheal intubation (ATI) procedure has to ensure that the patient is comfortable, without rejecting act during laryngoscopy-intubation, and that there is no arithmia nor increasing blood tension [11]. Awake tracheal intubation (ATI) remains the gold standard for airway management in the patients with a predicted difficult airway. ATI should be considered in any case with predictors of difficult airway management. Careful airway preparation and sedation can significantly improve the success rate of ATI [12].

This patient was in hypertension condition, therefore awake intubation, she had to be kept not to have fluctuated blood tension. Combination of several medicine were given to have light sedative, and also analgesia to avoid blood tension rise during laryngoscopy and intubation, and also patient felt comfortable.

Combination of local anesthesia, tranquilizer midazolam, analgesia fentanyl, and dexmedetomidine are giving ideal condition for awake intubation.

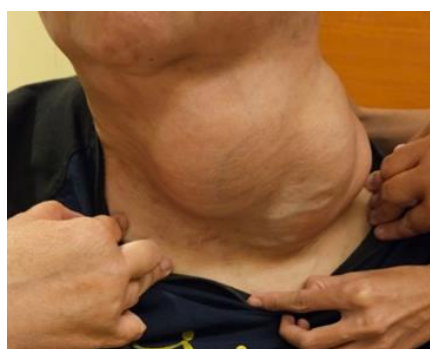Case

History

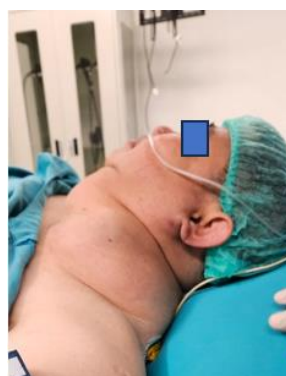Patient complained about the lump on her neck since 10 years ago. Currently, she also had a problem with asthma, especially when she was lying down. Therefore she came to the surgeon and planned to do tumor lifting. The patient had histories of bronchial asthma, gastritis, hypertension, and diabetes melitus and she consumed linagliptin (trajenta) 5 mg 1 x 1, metformin and empagliflozin (Jardiance duo), salbutamol, and teofilin (teosal), angiotensin receptor blocker (candesartan) 8 mg 1x1.

Physical examination

A female patient, 55 years old with giant struma. Her weight is 105 kg, height 165 cm, body mass index (BMI) 38.6, and morbid obesity. During airway examination, it was found that open mouth >3 cm, Mallampati score 4, neck circumference 64 cm (**Figure 1**), and thyromental distance 2 fingers. Blood tension was 150/80 mmHg, pulse 83 x/minutes, respiration 21 x/minutes, temperature 36.6°C, SpO₂ 93% within room air.



a)



b)

Figure 1. Giant struma

Laboratory test

Table 1. Blood test result preoperative

Test	Result	Reference Value	Unit
ROUTINE HEMATOLOGY			
Hemoglobin	11.4	13.1-17.2	g/dL
Erythrocyte	5.62	4.20-5.60	10 ⁶ /uL
Hematocrite	36	39-50	%
MCV	64	81-101	fL
MCH	20	27-35	Pg/cell
MCHC	32	32-36	g/dL
RDW	15.7	11.5-14.5	%
Leucocyte	9,650	3,66-10,600	/uL
Diff count			
Eosinofil	2	0-3	%

Basophyl	0	0-2	%
Neutrophil Stem	0	3-5	%
Neutrophyl Segment	68	50-70	%
Lymphocyte	24	18-42	%
Monocyte	6	2-11	%
Thrombocyte	310,000	150,000-450,000	/uL
HEMOSTASIS FUNCTION APTT			
Patient (APTT)	24.7	22.1-28.1	detik
Controlled (APTT)	25.2		
CLINICAL CHEMISTRY			
RENAL FUNCTION			
Ureum	13.8	12.8-42.8	Mg/dL
Creatinin	0.59	0.9-1.3	Mg/dL
eGFR	114	Normal: >90 Slightly decreased: 60-89 Low to moderate: 45-59 Moderate to severe:30-44 Very decreased: 15-29 Renal Failure: <15	
Fasting blood glucose	273	<100 Diagnosis DM \geq 200	Mg/dL
HbA1c	9.0	Normal: <5.7 Prediabetes 5.7-6.4 Diabetes \geq 6.5	%
ENDOCRINE & METABOLISM			
TSHs	0.8279	0.35-4.94	uIU/mL
Free T4	0.76	0.70-1.48	Ng/dL
LIVER FUNCTION			
SGOT	30	0-37	U/L
SGPT	34	0-50	U/L

Fasting blood glucose and HbA1c level indicate the patient has diabetes mellitus. The result of other test showed that it was within normal limits.

ECHO:

Normal all chamber

Normal all valve

Normal LV function

Normokinetic at rest

Photos of air column

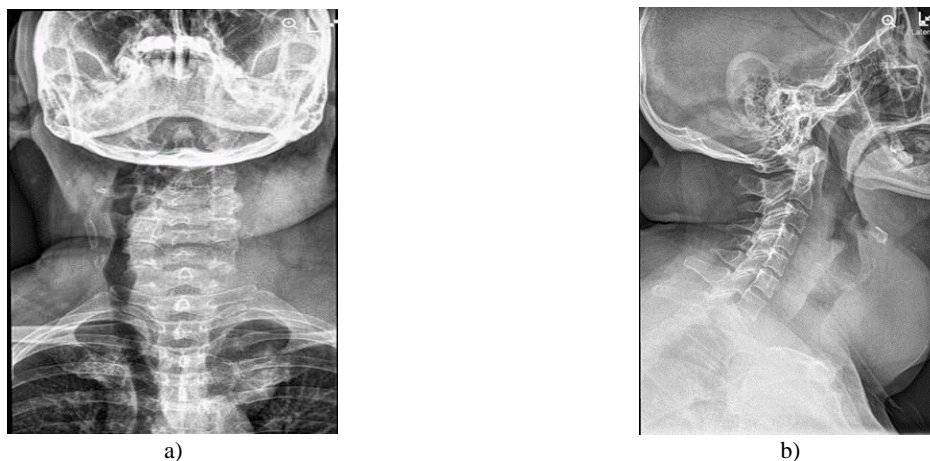


Figure 2. Air column to see the airway (Patient with physical status ASA 3).

Anesthesia management

Since we had assumption that the patient would experience difficult ventilation and intubation, awake-trachea intubation was done. Some tools were prepared such as a direct laryngoscope, endotrache tube (ETT) non kinking, stylet/mandrin, bougie, and suction. There were limited tools, we didn't have a laryngoscope video. Patient was positioned in a Ramped position, then she was given a standard anesthesia monitor, was given binasal oxygen 3 L/minutes, then midazolam 2 mg and fentanyl 50 µg through intravenous. Lidocain spraying was done in the pharyng area and

lidocain through intravenous was also given at 1 mg/kgBB. Laryngoscopy was conducted several times and additional midazolam 1 mg and dexmedetomidine 0.4 µg/kg/hour were given. Intubation could be done after almost 30 minutes and after ETT entered, it was tested by connecting it to the anesthesia machine. After ensuring that ETT was entered, the patient was given propofol 200 mg, additional fentanyl 150 µg, and atracurium 50 mg, while dexmedetomidine was stopped. Anesthesia maintenance was given with N₂O/O₂ and sevoflurane. Patient was also given tranexamic acid 1 gram and carbazochrome Na sulfonate (adona AC 17) 50 mg intravenous.

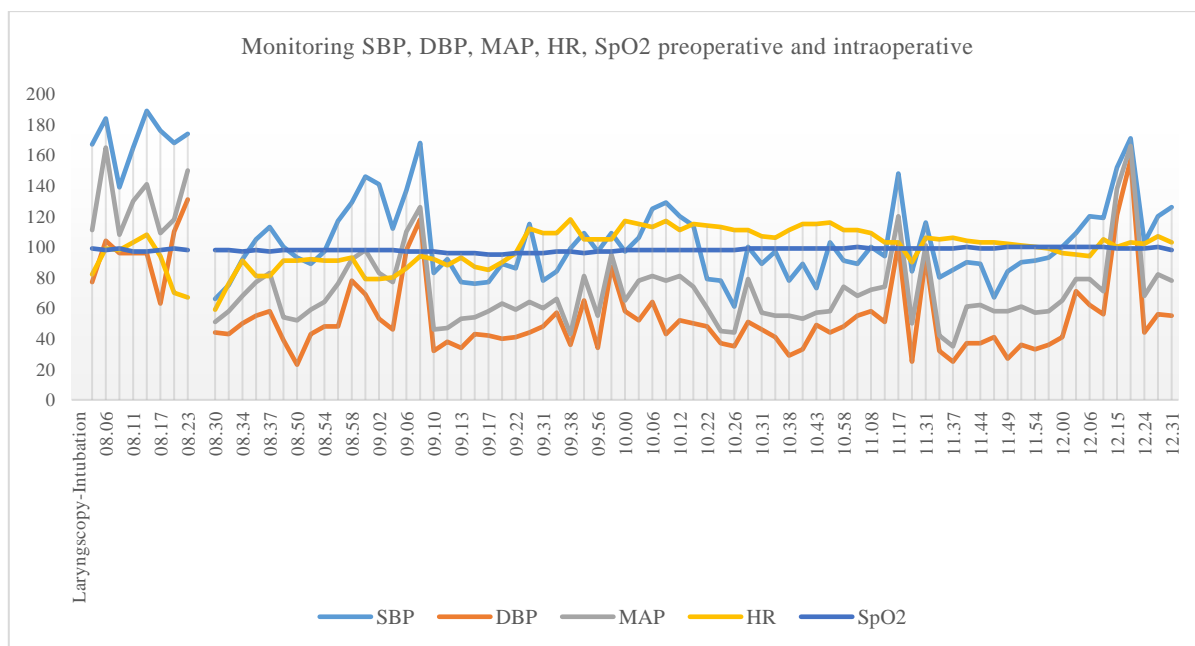


Figure 3. Monitoring SBP, DBP, MAP, HR, and SpO₂ preoperative and intraoperative.

Note: SBP = systolic blood pressure; DBP = diastolic blood pressure, MAP = mean arterial pressure; HR = heart rate; SpO₂ = peripheral oxygen saturation.

During periods of hypotension, first ephedrine is then replaced with vascon, and finally combined vascon and Dobutamine.

The bleeding amount was 1200 mL. The fluid that was given was RL 1000 mL and colloid gelofusin 1000 mL. Based on body weight and preoperative Hb level (Table 1), bleeding 1200 mL does not require blood transfusion. When blood tension was decreasing, the patient was given ephedrine. Since the blood tension was still low, the patient was given vascon and finally the combination of vascon and dobutamine. After the surgery was done, and as soon as the patient was fully awake, extubation was conducted inside the surgery room.

Postoperative management

Post-operative patients are treated in high care units. During periods of hypotension, given combined vascon and dobutamine. Dobutamine is infused at 2 to 20 mcg/kg/min to augment cardiac output through heightened myocardial contractility. Norepinephrine (NE) is favoured for its significant vasoconstrictive action and is administered continuously at 0.01 to 0.1 mcg/kg/min. Both medications require precise titration based on patient response, with adjustments made to optimize therapeutic effects while monitoring vital signs and clinical outcomes (Figure 4, Table 2). As conditions improve, dosages are gradually reduced to prevent rebound effects and ensure a safe discontinuation of therapy.

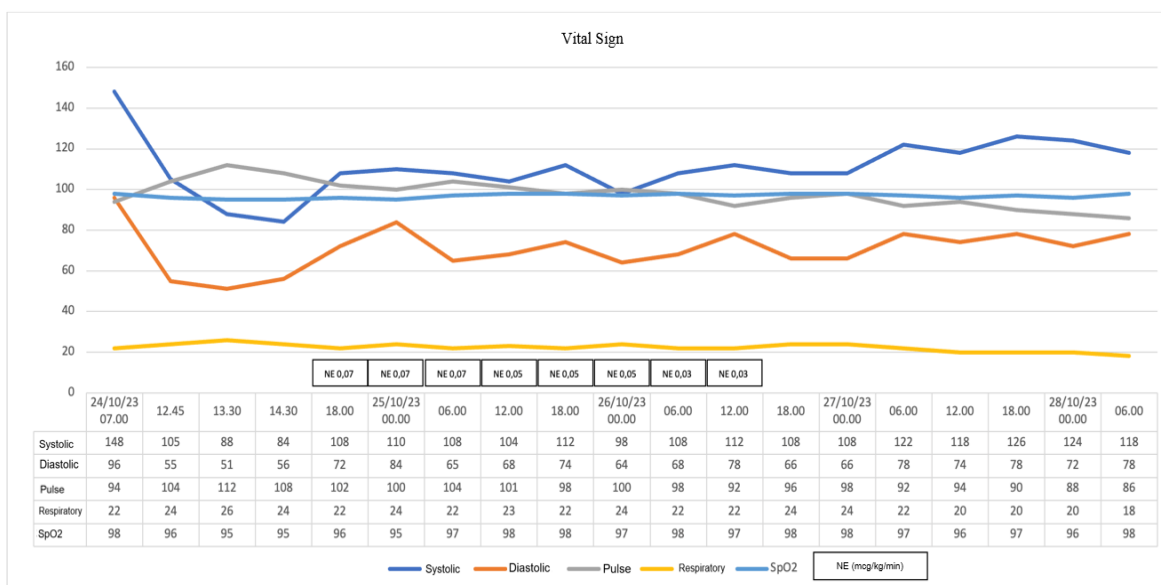


Figure 4. Monitoring SBP, DBP, MAP, HR, SpO₂ postoperative.

Note: SBP = systolic blood pressure; DBP = diastolic blood pressure, MAP = mean arterial pressure; HR = heart rate; SpO₂ = peripheral oxygen saturation.

Table 2. Blood test result postoperative

Date	Time	Haemoglobin	Haematocrit	Leucocytes	Thrombocytes	Lactate	pH	pCO ₂	pO ₂	HCO ₃	Base Excess (BE)
October 24, 2023	14.30	10,7	32,4	10.600	178.000	2,6	7,327	28,2	135,4	19,8	-3,8
	17.30	-	-	-	-	2,2	7,337	24,6	138,4	23,1	-1,8
October 24, 2023	05.00	9,8	30,2	14.800	190.000	1,8	7,345	24,2	142,2	25,4	-0,8
October 24, 2023	05.00	10,4	31,1	15.600	185.000	1,6	7,342	27,2	148,2	28,4	-0,6
October 24, 2023	05.00	10,8	32,2	18.400	197.000	-	-	-	-	-	-

Results and Discussion

The reason for awake tracheal intubation in this patient because there was the assumption that the patient would have difficulties in ventilation and intubation. The patient had morbid obesity, a score of Mallampati 4, neck diameter 64 cm, thyromental distance of 2 fingers and she also had giant struma with air column shifting to the left (Figures 1 and 2). With clinical conditions like this, it is estimated that there will be difficulties in intubation [13-15]. In cases where difficult intubation is suspected, intubation is done when the patient is awake, so he/she can obey command, able to breath spontaneously which is called awake trachea intubation [16].

Awake intubation procedure is uncomfortable for patients and possible causes blood tension rise and arithmia. In order to give comfortability to patients, and to avoid blood tension and pulse rise during awake intubation, the patient was given intravena medicine, such as midazolam, fentanyl, lidocaine, and dexmedetomidine [17,18].

The purpose of midazolam is as antianxiety and amnesia, fentanyl as analgetic, lidocain spraying as local anesthesia, intravena lidocain to prevent blood tension rise during laryngoscopy intubation, and dexmedetomidine to give tranquilizer effect and

analgetic. Since the patient was having obesity, the dose for ATI was adjusted per kg of weight [17, 18].

The pulse and tension was relatively steady (Figure 3). In line with the title, the purpose of this case is to report a successful rate in awake intubation procedure using direct laryngoscopy, stylet/mandrin, and bougie.

The bleeding could be overcome with crystalloid and colloid. Total bleeding was 1200 ml replaced with crystalloid 1000 mL and colloid gelofusin 1000 ml. Decreasing in blood tension, was not cause by bleeding (blood tranfusion and fluid was adequate), but from medicine effect that was given for ATI needs. There was also blood tension decreasing that needed efedrin, then vascon and dobutamine (Figure 3).

Dexmedetomidine is alpha 2-agonis which can cause blood tension to decreasing and pulse. Although ATI was done, the dexmedetomidine dose was only 0.4 ug/kg bw/hour and was still a small dose, but the combination of medicine with lidocain and fentanyl resulted in the effect of lowering significant blood tension [17, 18].

Obesity is defined as body mass index (BMI) >30 kg / m², while those who have BMI >35 and >55 kg / m² were considered morbid obese and super morbid obese. This patient had a BMI of 38.6 [12]. Obesity is a major health problem that influences each organ system and is said to be related to many health

consequences including risk-increasing of coronary artery illness (CAD), dislipidemia, hypertension, diabetes mellitus (DM), obstructive sleep apnoe (OSA). For anesthesiologists, problems in airway management, ventilation, co-morbid management, anesthesia dose, and post-surgery management. Like obesity deals with a lot of chronic medical condition, post-surgery history, and physical examination [14, 15].

Obesity possibly worsen by 30 % from the difficult intubation or failure. Mallampati class ≥ 3 and neck diameter ≥ 43 cm, thyromental 2 fingers related to increasing risk of difficult intubation. Ideal body weight is important because controlled ventilation (Vt) is based on "Prediction" or Ideal Body Weight (IBW) and anesthesia is given based on IBW or Lean Body Weight (LBW); not actual body weight (TBW) [14, 15].

Pharmacologic consideration has to be the main focus. Anesthesia medicine was given based on BW in routine surgery, but this might not be applied to obese patient because most anesthesia medicine are very lipophilic. To achieve adequate serum concentrations, a big initial dose is needed and the dose is calculated based on. However, the maintenance dose needs to be reduced and calculated based on IBW because it has longer half elimination [14, 15].

Intubation for general anesthesia has several problems because of large neck circle, high score Mallampati, intolerant lying position, and posterior servical fat which can exaggerate bending position. During intubation use "stacked" or "ramped position", preoxygenation in position reverse Trendelenburg [14, 15].

In this kind of patient difficult ventilation situation might happens because BMI >35 plus other anatomy findings (Mallampati score >3 , neck diamter > 43 cm, short thyromental distance < 3 fingers or < 6 cm), short thick neck. Intubation problem is three times possibly happening to obesity patient than to normal weight patient [14, 15, 19].

Conclusion

With medicine combination, in order to achieve mild sedation with a combination of analgetic, and antianxiety-sedative, when ATI is done there is no increasing insignificant blood tension and pulse. However, even though the effect during ATI is good without blood tension increasing, pulse, and the procedure is succesfully done, during intraoperative and post-surgery there is increasing in blood tension and this has to be solved with vascon and dobutamine. Medicine dose for ATI is based on body weight per kg, but because the patient consumes many kinds of medicine and is obese, the medicine effect that decreasing blood tension becoming significant.

Acknowledgments: None

Conflict of interest: None

Financial support: None

Ethics statement: None

References

1. Alghamdi S, Alhazmi K. Appendectomy impact on inflammatory bowel diseases: A meta-analysis. *World J Environ Biosci.* 2021;10(1):13-8.
2. Altowigri A, Mirghani HO. Blount disease, Vitamin D deficiency, and associated comorbidities: A review and meta-analysis. *World J Environ Biosci.* 2021;10(1):5-8.
3. ATLS Advanced Trauma Life Support. Chapter 2. Airway and ventilatory management. 10th ed. American College of Surgeons. 2018.
4. Kollmeier BR, Boyette LC, Beecham GB, Desai NM, Khetarpal S. Difficult Airway. In: StatPearls [Internet]; 2023.
5. Apfelbaum JL, Hagberg CA, Caplan RA, Blitt CD, Connis RT, Nickinovich DG, et al. American society of anesthesiologists task force on management of the difficult airway. Practice guidelines for management of the difficult airway: an updated report by the American Society of Anesthesiologists Task Force on Management of the Difficult Airway. *Anesthesiology.* 2013;118(2):251-70.
6. Souvatzis X, Askitopoulou H. Definition of difficult tracheal intubation. *Eur J Anaesthesiol.* 2008;25(8):694-5.
7. Huitink JM, Bouwman RA. The myth of the difficult airway: Airway management revisited. *Anaesthesia.* 2015;70(3):244-9.
8. Hayashida K, Matsumoto S, Kitano M, Sasaki J. Predictive value of quick surgical airway assessment for trauma (qSAT) score for identifying trauma patients requiring surgical airway in emergency room. *BMC Emerg Med.* 2018;18(1):48.
9. Mendonca C, Tourville CC, Jefferson H, Nowicka A, Patteril M, Athanassoglou V. Fiberoptic-guided tracheal intubation through i-gel® and LMA® Protector™ supraglottic airway devices- a randomised comparison. *Anaesthesia.* 2019;74(2):203-10.
10. Ahmad I, El-Boghdadly K, Bhagrath R, Hodzovic I, McNarry AF, Mir F, et al. Difficult airway society guidelines for awake tracheal intubation (ATI) in adults. *Anaesthesia.* 2020;75(4):509-28.
11. Ahmad I, Onwochei DN, Muldoon S, Keane O, El-Boghdadly K. Airway management research: A systematic review. *Anaesthesia.* 2019;74(2):225-36.
12. Vora J, Leslie D, Stacey M. Awake tracheal intubation. *BJA Educ.* 2022;22(8):298-305.
13. Sabharwal A, Christelis N. Continuing education in anaesthesia. *Crit Care Pain.* 2010;10(4):99-103.
14. Brodsky JB, Lemmens HJM, Brock-Utne JG, Vierra M, Saidman LJ. Morbid obesity and tracheal intubation. *Anesth Analg.* 2002;94(3):732-6.
15. Brodsky JB. Anesthesia for bariatric surgery. Stanford University Medical Center, Stanford, California. February 26, 2018

16. Leslie D, Stacey M. Awake Intubation. *Contin Educ Anaesth Crit Care Pain*. 2015;15(2):64-7.
17. Scott-Warren VL, Sebastian J. Dexmedetomidine: Its use in intensive care medicine and anaesthesia. *BJA Educ*. 2016;16(7):242-6.
18. Tang Z, Chen Q, Wang X, Su N, Xia Z, Wang Y. A systematic review and meta-analysis of the safety and efficacy of remifentanyl and dexmedetomidine for awake fiberoptic endoscope intubation. *Medicine (Baltimore)*. 2021;100(14):1-7.
19. Juvin P, Lavaut E, Dupont H, Lefevre P, Demetriou M, Dumoulin JL, et al. Difficult tracheal intubation is more common in obese than in lean patients. *Anesth Analg*. 2003;97(2):595-600.