

# Comparison of TGF- $\beta$ 1 in corneal laceration with or without *Aloe vera* gel treatment

Nur Atik<sup>1\*</sup>, Muhamad Arif Rachman Sururi<sup>2</sup>, Raden Angga Kartiwa<sup>3</sup>

<sup>1</sup>Department of Biomedical Sciences, Faculty of Medicine, Universitas Padjadjaran, Bandung, Indonesia. <sup>2</sup>Faculty of Medicine, Universitas Padjadjaran, Bandung, Indonesia. <sup>3</sup>Department of Ophthalmology, Universitas Padjadjaran/Cicendo National Eye Hospital, Bandung, Indonesia.

**Correspondence:** Nur Atik, Department of Biomedical Sciences, Faculty of Medicine, Universitas Padjadjaran, Bandung, Indonesia. n.atik@unpad.ac.id

## ABSTRACT

Corneal stromal wound healing is slower than other connective tissues, which is thought to be partly controlled by various matrix metalloproteinases. Transforming Growth Factors –  $\beta$ 1 (*TGF- $\beta$ 1*) appears in the three main phases of the wound healing process as a mediator and plays a role in the final matrix formation phase. *Aloe vera* has a glucomannan component, which can accelerate the production of TGF- $\beta$ . This study aimed to compare the expression of TGF- $\beta$  in corneal lamellar lacerations in mice treated with and without *Aloe vera* gel therapy. This was an experimental study using a mice model treated with a corneal laceration wound. The sample size obtained was 20 samples, which were grouped into four types of treatment. TGF- $\beta$ 1 immunohistochemistry expression on the first day in the strong positive category showed 10% without gel and 50% with gel. In contrast, the same category on the third day showed 10% without gel and 90% with gel. There were two significant differences upon these two days ( $p = 0.013$ ,  $p = 0.003$ ). Apart from the two groups treated with *Aloe vera* gel, the results were then compared between the first and third days ( $p = 0.141$ ) and determined the expression of TGF- $\beta$ 1 on wound healing time. Assessment of TGF- $\beta$ 1 expression in the healing process of laceration in mice subjected to *Aloe vera* gel showed higher results.

**Keywords:** *Aloe vera*, Corneal healing process, Immunohistochemistry, TGF- $\beta$ 1

## Introduction

The Cornea is the main component of eye refraction that is avascular and transparent. Corneal disorders can interfere with an optical performance and reduce productivity. Eye injuries are generally divided into open and closed globe injuries. Closed wounds, such as corneal lamellar lacerations are caused by sharp objects. Corneal lacerations management is crucial because the result may affect vision post-wound-healing. Corneal wound management is to maintain the condition of the cornea and avoid possible complications from the injury [1-4].

Corneal wound healing is a complex process involving all cellular layers and mediators to assist each other's processes. Each layer responds differently. Signaling the process of cell proliferation

and differentiation is mediated via autocrine and paracrine, and are assisted by several mediators shown to significantly improve epithelial wound healing. There are three phases in the epithelial wound healing process; the latent phase of the first 4-6 hours, cell migration and adhesion 24-36 hours, cell proliferation phase starting from 36 hours onwards [5]. Wound healing is influenced by many factors including wound size, depth, causative agent, and tear quality. Various peptide growth factors appear to play an essential role in the regulation of normal corneal wound healing [6].

Transforming growth factor-beta (*TGF- $\beta$* ) is a multifunctional cytokine that modulates proliferation, growth differentiation, adhesion, and cell survival [7]. Its growth factor also plays a role in extracellular matrix protein production. TGF- $\beta$  is a secretion protein consisting of three isoforms, namely TGF- $\beta$ 1, TGF- $\beta$ 2, and TGF- $\beta$ 3. TGF- $\beta$ 1 is the main member of this group whose role is widely known. Furthermore, it plays a role in the inhibition and stimulation of cell proliferation, controls the synthesis and degradation of the extracellular matrix, and mediates cells and tissues' response to injury. TGF- $\beta$ 1 appears in

### Access this article online

Website: [www.japer.in](http://www.japer.in)

E-ISSN: 2249-3379

**How to cite this article:** Atik N, Sururi MAR, Kartiwa RA. Comparison of TGF- $\beta$ 1 in corneal laceration with or without *Aloe vera* gel treatment. J Adv Pharm Educ Res. 2021;11(1):120-4. <https://doi.org/10.51847/Jq2Ck35>

This is an open access journal, and articles are distributed under the terms of the Creative Commons Attribution-Non Commercial-ShareAlike 4.0 License, which allows others to remix, tweak, and build upon the work non-commercially, as long as appropriate credit is given and the new creations are licensed under the identical terms.

three main phases of the wound healing process as a mediator and plays a role in the final phase of matrix formation [8].

Herbal medicine in the wound healing process is one of the examples of alternative medicine. Indonesia, recognized as a tropical country, is very abundant in its biodiversity [9]. Many different plants live and grow in tropical countries, such as *Aloe vera*. The plants can also be obtained at affordable prices as a treatment option. *Aloe vera* has many active components that are needed for the wound healing process; it has anti-inflammatory, antiseptic and antibiotic properties [10]. Wozniak in his research stated that epithelial wound healing is better when using *Aloe vera* gel because there are no toxic effects [11, 12].

In the process of wound healing, *Aloe vera* is known to stimulate growth factors, increase fibroblast function, and the formation of new blood vessels so that it can accelerate wound healing and closure [12-14]. The healing process for corneal wounds starts from the first 6 hours and lasts for about 72 hours after trauma [15, 16]. This study aimed to determine the role of *Aloe vera* gel on TGF-β1 in mice corneal lacerations treated with and without *Aloe vera* gel therapy.

## Materials and Methods

### Animal model

This study was an experimental animal study using mice treated with a corneal laceration. The ethical clearance was obtained from the Research Ethics Committee, Universitas Padjadjaran with the ethical number 740/UN6.KEP/EC/2020. Corneal laceration trauma was performed using marked blades to injure the central area of the mouse cornea. The sample size was determined using Mead's Resource Equation Method, and 20 samples were obtained by grouping 4 types of treatments (5 mice

per group). The first and third groups were treated with ofloxacin antibiotics and artificial tears. The second and fourth groups were given ofloxacin antibiotics and *Aloe vera* gel. The first and third groups were enucleated after one day of treatment, and the second and fourth groups were done after three days of treatment. Observations were made on the model of animal eye tissue using Immunohistochemistry staining to determine TGF-β1 expression.

### Analysis of TGF-β1 expression by Immunohistochemistry

The sample of this research was tissue enucleated from mice eyes. The tissue was preserved with formaldehyde and made into paraffin blocks. Paraffin-embedded parts were performed immunohistochemistry procedures for anti-TGF-β1 antibody according to procedures in previous studies [17]. The scores of distribution and intensity of immunohistochemistry are divided into 4 categories, which are negative, weakly positive, moderately positive, and strongly positive with scales of 1 to 4, respectively.

### Statistical analysis

Differences in semi-quantitative histopathological assessments of groups with and without *Aloe vera* gel treatment were analyzed by differentiation test between two independent samples using Chi-square and Mann Whitney tests. The analysis was performed using the statistical program SPSS Windows Release version 26.0.

## Results and Discussion

**Table 1. Comparison of TGF-β1 expression in groups with and without *Aloe vera* therapy on the first day**

Treatment	TGF-β1 IHC Score			P-value
	Weakly Positive	Moderately Positive	Strongly Positive	
Group 1 - Day 1 (Ofloxacin + Artificial tears)	4 40.0%	5 50.0%	1 10.0%	0.013
Group 2 - Day 1 (Ofloxacin + <i>Aloe vera</i> Gel)	0 0.0%	5 50.0%	5 50.0%	

Immunohistochemistry results of TGF-β1 expression in groups with and without *Aloe vera* gel for day one and day three can be seen in **Tables 1 and 2** below.

**Table 2. Comparison of TGF-β1 expression in groups with and without *Aloe vera* therapy on the third day**

Treatment	TGF-β1 IHC Score			P-value
	Weakly Positive	Moderately Positive	Strongly Positive	
Group 3 - Day 3 (Ofloxacin + Artificial tears)	1 10.0%	8 80.0%	1 10.0%	0.003
Group 4 - Day 3 (Ofloxacin + <i>Aloe vera</i> Gel)	0 0.0%	1 10.0%	9 90.0%	

**Table 1** shows the results of statistical analysis using the *Mann Whitney* alternative *Chi-Square*. There was a difference in the expression of TGF-β1 between the *Aloe vera* gel treatment and without the *Aloe vera* gel treatment groups on the first day (**Table 1**).

The expression result of TGF-β1 in the group without *Aloe vera* gel showed 10% strongly positive, 50% moderately positive, and 40% weakly positive values. In contrast, the TGF-β1 expression in the *Aloe vera* gel treatment group showed results with 50% strongly positive and 50% moderately positive values. There

were statistically significant differences between the two treatment groups with a P-value <0.05.

Assessment of the results for day three in the group without *Aloe vera* gel showed positive results, with 10% strongly positive, 80% moderately positive, and 10% weakly positive values. Meanwhile, the *Aloe vera* gel group showed a different

proportion, with 90% strongly positive and 10% moderately positive values. The results of the statistical analysis using the *Kolmogorov Smirnov* alternative *Chi-Square* test showed a significant difference in the TGF-β1 expression on the third day with P-value <0.05.

**Table 3. Comparison of TGF-β1 expression in groups without *Aloe vera* therapy on different days**

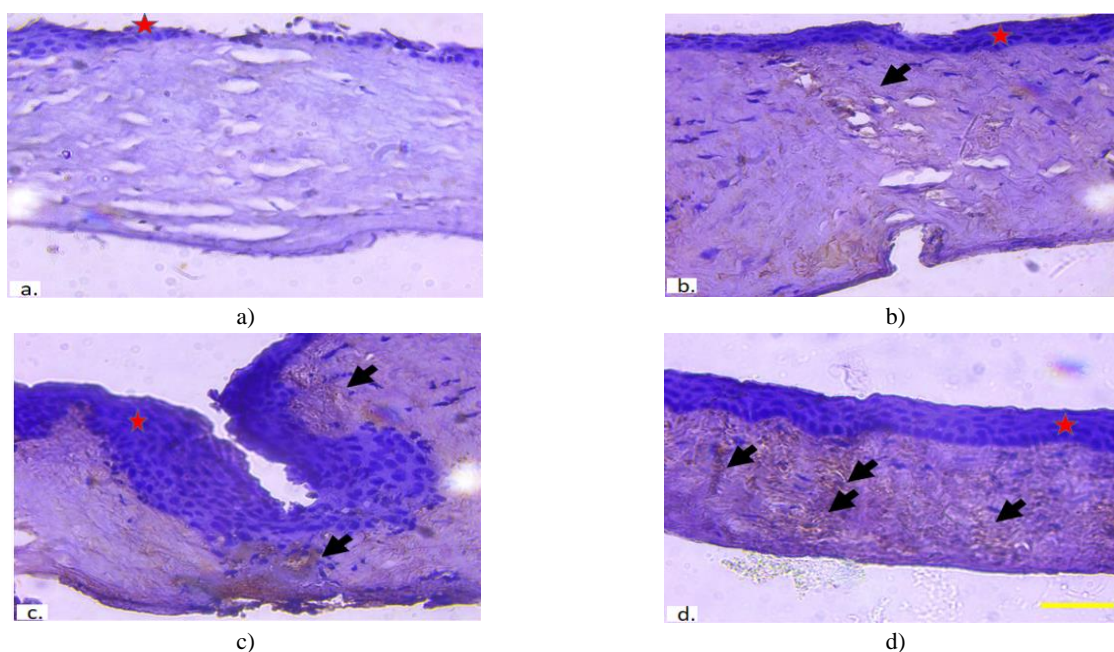
Treatment		TGF-β1 IHC Score			P Value
		Weak Positive	Moderate Positive	Strong Positive	
Group 1 - Day 1 (Ofloxacin + Artificial tears)		4	5	1	0.759
		40.0%	50.0%	10.0%	
Group 3 - Day 3 (Ofloxacin + Artificial tears)		1	8	1	
		10.0%	80.0%	10.0%	

**Table 4. Comparison of TGF-β1 expression in groups with *Aloe vera* therapy on different days**

Treatment		TGF-β1 IHC Score			P-Value
		Weakly Positive	Moderately Positive	Strongly Positive	
Group 2 - Day 1 (Ofloxacin + Aloe vera Gel)		0	5	5	0.141
		0.0%	50.0%	50.0%	
Group 4 - Day 3 (Ofloxacin + Aloe vera Gel)		0	1	9	
		0.0%	10.0%	90.0%	

Furthermore, the immunohistochemistry results of the TGF-β1 expression in the same treatment group, when being compared to different days, can be seen in **Tables 3 and 4**. The healing process is time-dependent. Therefore, it showed no significant differences between the two treatment groups without *Aloe vera* gel on different days with a value of  $p=0.759$ . We also showed that the TGF-β1 expression results were not significant using the alternative *Chi-Square* test *Fisher's Exact* test with P-value=0.141 (**Table 4**). This assessment aimed to determine the relationship between TGF-β1 expression with time during the process of corneal wound healing.

This study's hypothesis is to find out that there are differences in the expression of TGF-β1 for the group with and without *Aloe vera* gel treatment. The assessment result of TGF-β1 expression in the group with *Aloe vera* gel therapy was compared with the group without *Aloe vera* gel therapy on the first and third days using the *Chi-Square* test alternative to the *Kolmogorov Smirnov* test, and the *Mann-Whitney* test gave significant results with ( $p < 0.05$ ), (**Tables 1 and 2**). Meanwhile, groups with the same treatment on different days showed insignificant results ( $p > 0.05$ ) (**Tables 3 and 4**).



**Figure 1. Immunohistochemistry observation for TGF-β1 expression**

The mice were sacrificed and stain with an anti-TGF-β1 antibody with IHC methods. The mice were divided into 4 groups with different treatments. Some groups were treated with ofloxacin with artificial eye teardrops and sacrificed on the first day (a) and third day (c). Other groups were treated with ofloxacin with *Aloe vera* on the first day (b) and third day (d). The figure shows anterior corneal epithelium (red star) and the TGF-β1 expression (black arrows). Yellow bar, 50 μm.

The expression of TGF- $\beta$ 1 in corneal tissue reflects its complex role in maintaining corneal integrity and promoting corneal wound healing. In the process of wound healing of the epithelial layer that occurs 24 hours after trauma, one of the end polysaccharide chain containing mannose in glucomannan binds to the *mannose-6-phosphate* (M-6-P) receptor, and *transforming growth factor* (TGF- $\beta$ ) stimulates keratocytes to produce collagen and proteoglycan fibers, thus accelerating the wound healing process [18]. Atiba *et al.* reported a better epithelialization process with *Aloe vera*'s administration compared to physiological solutions in diabetic rats treated with basic trauma. The study reported an increase in the expression of TGF, which accelerated the healing of skin wounds and increased epithelialization by administering *Aloe vera* [13, 18, 19]. Several *in vitro* studies have shown that *Aloe vera* components such as mannose stimulate macrophages by binding to surface mannose receptors [19, 20]. Carbohydrate components such as polysaccharides, mannose, and acemannan will activate macrophages in the wound binding to mannose receptors, a possible explanation for the accelerated production of TGF- $\beta$ 1 [18, 21]. Immunohistochemistry results showed immunoreactive against anti-TGF- $\beta$ 1 antibodies so that the streak was clear.

The cytokine TGF  $\beta$ 1 increases the mitosis of fibroblast cells in epithelial cells, thereby increasing the formation of angiogenesis through the expression of *Vascular Endothelial Growth Factor* (VEGF). The formation of new blood vessels will further assist the migration process of keratinocytes, fibroblasts, and endothelial cells in the lesions, thereby accelerating tissue repair and epithelialization. In addition, binding to growth factors stabilizes the activity of these factors and protects against heat and enzyme degradation [22, 23].

The role of (TGF- $\beta$ ) is needed in wound healing, to be precise, when the inflammatory phase goes to the proliferation phase in the wounds. Previous studies have shown TGF- $\beta$ 1 expression is detectable 24 hours after injury. TGF- $\beta$ 1 increases rapidly after injury and reaches its peak level 72 hours after the injury towards mice skin. The TGF- $\beta$ 1 activity in corneal wounds showed slightly different results in the TGF- $\beta$ 1 expression in the skin or injured tissue. There is an increase post-injury and it reaches its peak level 48-72 hours after injury, after which it tends to be constant or even gradually decreases [24, 25]. Previous studies have suggested that TGF- $\beta$ 1 signalling is lost in chronic wounds and caused them to not heal [26]. The Corneal stem cell therapy study mediated by Transforming Growth Factor have shown that there is no significant change in the expression of TGF- $\beta$ 1 hCSCC (human Corneal Stromal Stem Cell) in macrophage polarization (M0, M1, or M2) conditions [27]. This result is in accordance with the theory that all injured corneas heal within 72 hours, which means there is no significant difference compared to giving therapy on different days, even with *Aloe vera* gel.

## Conclusion

The assessment of TGF- $\beta$ 1 expression in the healing process of lamellar laceration in mice treated with *Aloe vera* gel showed higher results than without *Aloe vera* gel treatment.

**Acknowledgments:** This work was supported by a grant from the Ministry of Research and technology/BRIN of the Republic of Indonesia to Nur Atik.

**Conflict of interest:** None

**Financial support:** None

**Ethics statement:** None

## References

1. Vinuthinee N, Azreen-Redzal A, Juanarita J, Zunaina E. Corneal laceration caused by river crab. *Clin Ophthalmol* (Auckland, NZ). 2015;9:203-6.
2. Kuhn F, Morris R, Witherspoon CD, Mester V. The Birmingham eye trauma terminology system (BETT). *J Fr Ophthalmol*. 2004;27(2):206-10.
3. Lee SH. Management of corneal wounds: some practical tips. *Nepal J Ophthalmol*. 2009;1(2):146-50.
4. Zhi-Han L, Hui-Yin Y, Makmor-Bakry M. Medication handling Challenges among Visually Impaired Population. *Arch Pharm Pract*. 2017;8(1):8-14.
5. Wilson SE, Mohan RR, Mohan RR, Ambrósio Jr R, Hong J, Lee J. The corneal wound healing response: cytokine-mediated interaction of the epithelium, stroma, and inflammatory cells. *Prog Retin Eye Res*. 2001;20(5):625-37.
6. Ashby BD, Garrett Q, Willcox MD. Corneal injuries and wound healing—review of processes and therapies. *Austin J Clin Ophthalmol*. 2014;1(4):1-25.
7. Allam NA, Abdel-Hamid MS, Abdel-Azeim H. Pathogenic *E. coli* Virulence Traits Regarding Quantitative Cytokine Expression in Subclinical Mastitic Cows. *Int J Pharm Phytopharmacol Res*. 2018;8(2):45-58.
8. Grellner W, Vieler S, Madea B. Transforming growth factors (TGF- $\alpha$  and TGF- $\beta$ 1) in the determination of vitality and wound age: immunohistochemical study on human skin wounds. *Forensic Sci Int*. 2005;153(2-3):174-80.
9. Asadi N, Bahmani M, Shahsavari S, Asadi-Samani M. Identification and introduction of the medicinal plants used by honeybees in Markazi province. *Int J Pharm Phytopharmacol Res*. 2017;7(2):15-8.
10. Khan A, Khan A, Wazir NN, Ullah N, Khan OH. Relapse multifocal osteomyelitis secondary to septicemia: A case study. *Arch Pharm Pract*. 2017;8(1):31-4.
11. Rajeswari R, Umadevi M, Rahale CS, Pushpa R, Selvavenkadesh S, Kumar KS, et al. *Aloe vera*: the miracle

- plant its medicinal and traditional uses in India. *J Pharmacogn Phytochem.* 2012;1(4):118-24.
12. Woźniak A, Paduch R. Aloe vera extract activity on human corneal cells. *Pharm Biol.* 2012;50(2):147-54.
  13. Tester R, Al-Ghazzewi FH. Role of Glucomannans in Immunology. *J Pharm Pharm Sci.* 2017;20:97-114.
  14. Atik N, Nandika A, Dewi PI, Avriyanti E. Molecular mechanism of *Aloe barbadensis* Miller as a potential herbal medicine. *Sys Rev Pharm.* 2019;10(1):S32-9.
  15. Ljubimov AV, Saghizadeh M. Progress in corneal wound healing. *Prog Retin Eye Res.* 2015;49:17-45.
  16. Hardarson T, Hanson C, Claesson M, Stenevi U. Time-lapse recordings of human corneal epithelial healing. *Acta Ophthalmol Scand.* 2004;82(2):184-8.
  17. Atik N, Nanua NK, Avriyanti E. The aloe vera effect on cardiomyocytes and vegf-a expression in rats after cigarette smoke exposure. *Adv Sci Lett.* 2017;23(7):6658-61.
  18. Atiba A, Ueno H, Uzuka Y. The effect of aloe vera oral administration on cutaneous wound healing in type 2 diabetic rats. *J Vet Med Sci.* 2011;73(5):583-9.
  19. Quezada MP, Salinas C, Gotteland M, Cardemil L. Acemannan and fructans from *Aloe vera* (*Aloe barbadensis* Miller) plants as novel prebiotics. *J Agric Food Chem.* 2017;65(46):10029-39.
  20. Liu C, Leung MY, Koon JC, Zhu LF, Hui YZ, Yu B, et al. Macrophage activation by polysaccharide biological response modifier isolated from *Aloe vera* L. var. *chinensis* (Haw.) Berg. *Int Immunopharmacol.* 2006;6(11):1634-41.
  21. Chithra P, Sajithlal GB, Chandrakasan G. Influence of *Aloe vera* on the glycosaminoglycans in the matrix of healing dermal wounds in rats. *J Ethnopharmacol.* 1998;59(3):179-86.
  22. Takzaree N, Hadjiakhondi A, Hassanzadeh G, Rouini MR, Manayi A, Zolbin MM. Transforming growth factor- $\beta$  (TGF- $\beta$ ) activation in cutaneous wounds after topical application of aloe vera gel. *Can J Physiol Pharmacol.* 2016;94(12):1285-90.
  23. Pakyari M, Farrokhi A, Maharlooeei MK, Ghahary A. Critical role of transforming growth factor beta in different phases of wound healing. *Adv Wound Care.* 2013;2(5):215-24.
  24. Wang XJ, Han G, Owens P, Siddiqui Y, Li AG. Role of TGF $\beta$ -mediated inflammation in cutaneous wound healing. *J Invest Dermatol Symp Proc.* 2006;11(1):112-7.
  25. Carrington LM, Albon J, Anderson I, Kamma C, Boulton M. Differential regulation of key stages in early corneal wound healing by TGF- $\beta$  isoforms and their inhibitors. *Invest Ophthalmol Vis Sci.* 2006;47(5):1886-94.
  26. Pastar I, Stojadinovic O, Krzyzanowska A, Barrientos S, Stuelten C, Zimmerman K, et al. Attenuation of the transforming growth factor  $\beta$ -signaling pathway in chronic venous ulcers. *Mol Med.* 2010;16(3):92-101.
  27. Weng L, Funderburgh JL, Khandaker I, Geary ML, Yang T, Basu R, et al. The anti-scarring effect of corneal stromal stem cell therapy is mediated by transforming growth factor  $\beta$ 3. *Eye Vis.* 2020;7(1):1-4.